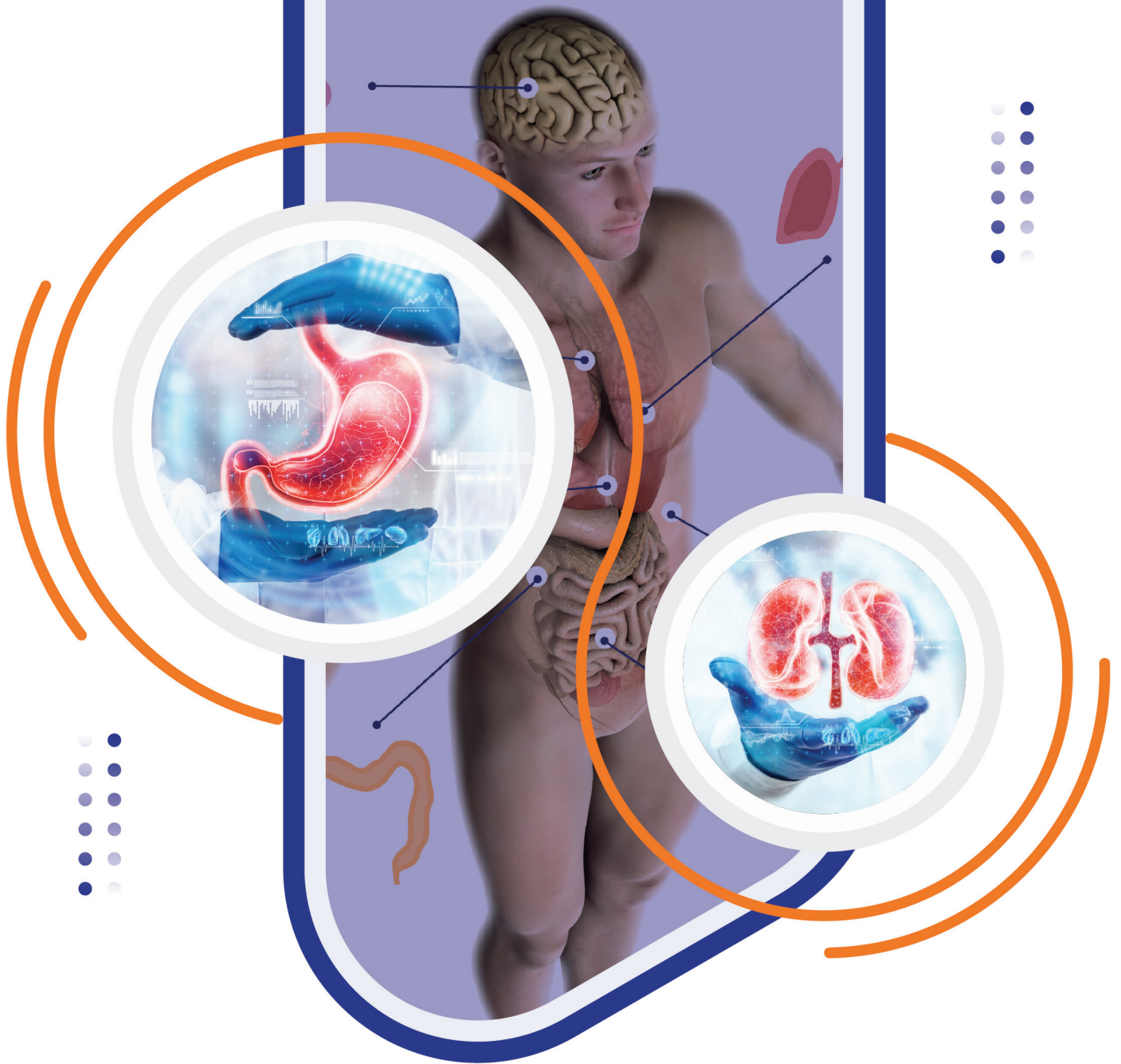

Internal Medicine

Internal Medicine

Overview

Internal Medicine, one of the most intellectually demanding medical specialties, focuses on the diagnosis and management of diverse diseases using a combination of pharmacological & non-pharmacological approaches, often involving small procedures. In this course, we invite medical students to embark on a comprehensive exploration of the main subspecialties within internal medicine, including cardiology, nephrology, and gastroenterology, among others.

A competent physician in internal medicine must possess a range of skills and knowledge acquired during clerkships. This includes developing a clinician's mindset, the ability to quickly and effectively understand complex patients, and strategic use of interventions, whether pharmacological or otherwise. Additionally, a comprehensive understanding of the gold standard management for common conditions informs the processes of screening and referral, leading to improved outcomes and enhanced quality of life for patients.

Topics

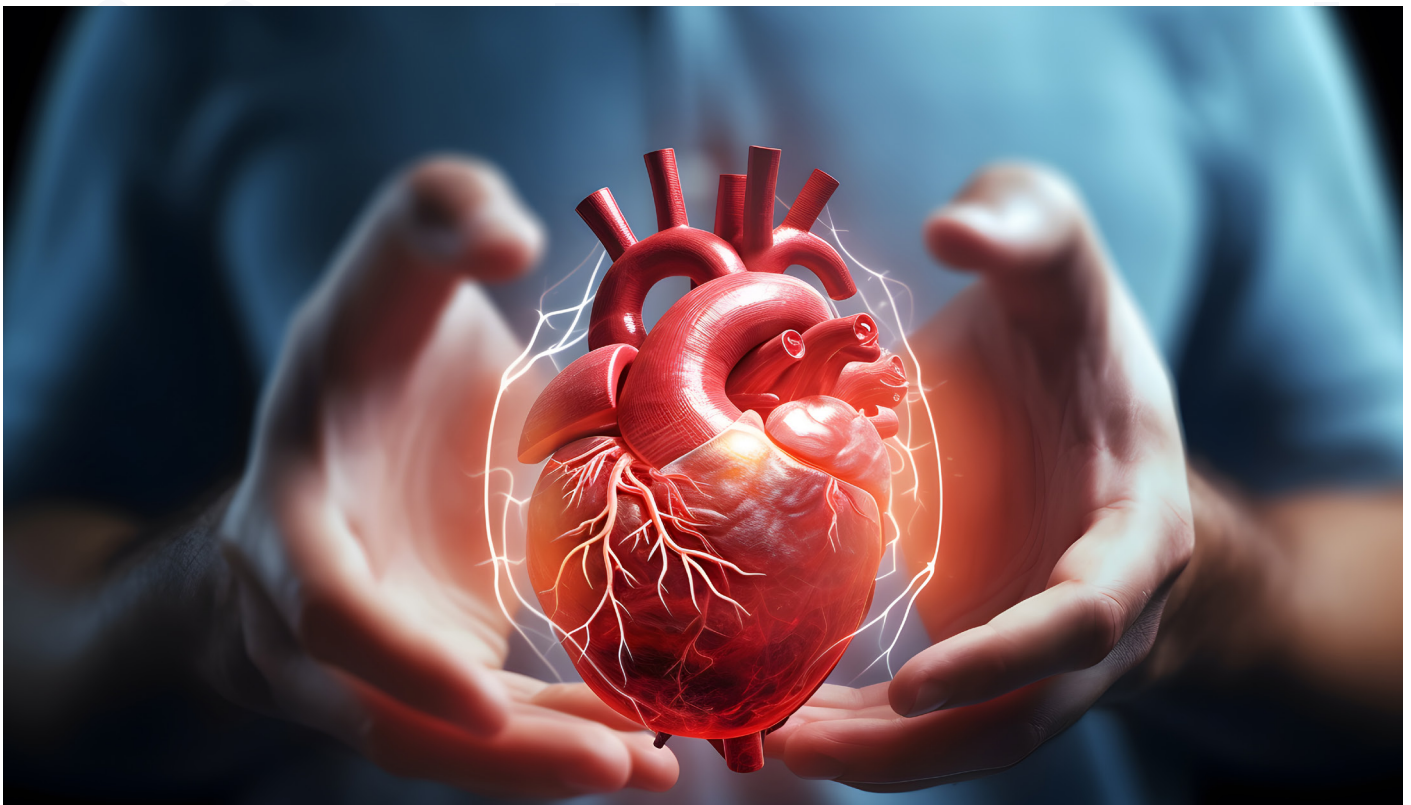Cardiology	088 Videos
Clinical Neurology	113 Videos
Dermatology	053 Videos
Endocrinology	053 Videos
Gastroenterology	014 Videos
Haematology	002 Videos
Infectious Diseases	099 Videos
Nephrology	015 Videos
Pulmonology	036 Videos
Radiology	038 Videos
Rheumatology	017 Videos
Vascular Medicine	078 Videos



Cardiology

Cardiology

- Cardiac Diseases 40 Videos
- Electrocardiogram (ECG) Interpretation 44Videos
- Cardiovascular Cases 30 Videos



Cardiac Diseases

- Definition – Heart Failure
- Pathophysiology – Heart Failure
- Types – Heart Failure
- Causes and Symptoms – Heart Failure
- Testing on Patients and Therapy – Heart Failure
- Classification – Congenital Heart Disease
- Obstructive Congenital Heart Lesions – Congenital Heart Disease
- Congenital Heart Lesions – Congenital Heart Disease
- Conclusion – Congenital Heart Disease
- Anomalous Coronary Arteries – Congenital Heart Disease
- Changing Concepts – Valvular Heart Disease
- Aortic Stenosis – Valvular Heart Disease
- Bicuspid Aortic Valve – Valvular Heart Disease
- Aortic Sclerosis – Valvular Heart Disease
- Aortic Regurgitation – Valvular Heart Disease
- Mitral Stenosis and Mitral Regurgitation – Valvular Heart Disease
- Tricuspid Regurgitation – Valvular Heart Disease
- Pbvlaque – Coronary Artery Disease
- Acute Coronary Syndrome – Coronary Artery Disease
- Six Areas of Consensus – Coronary Artery Disease
- Four Areas of Controversy – Coronary Artery Disease
- Diseases of the Heart Muscle – Cardiomyopathy
- Dilated Cardiomyopathy – Cardiomyopathy
- Secondary Dilated Cardiomyopathy – Cardiomyopathy
- Hypertrophic Cardiomyopathy – Cardiomyopathy
- Restrictive Cardiomyopathy – Cardiomyopathy
- Therapy – Cardiomyopathy
- Reading ECGs and Identifying Arrhythmias – Cardiac Dysrhythmia

- Conduction System – Cardiac Dysrhythmia
- ECG Trace – Cardiac Dysrhythmia
- Sinus, Atrial and Ventricular Rhythm – Cardiac Dysrhythmia
- Reading ECGs – Cardiac Dysrhythmia
- Complications of Hypertension – Hypertension
- Therapy – Hypertension
- Diuretics – Hypertension
- Renin Angiotensin Aldosterone System – Hypertension
- Beta and Calcium Channel Blockers – Hypertension
- Other Forms of Therapy – Hypertension
- Cardiac Trauma
- Cardiac Tumors

Electrocardiogram (ECG) Interpretation

- How to Read an Electrocardiogram (ECG): Introduction
- Cardiac Action Potential
- Standard 12 Lead ECG
- Systematic ECG Interpretation
- ECG Case: 22-year-old Man with Anterior Chest Pain
- Review of Normal ECG
- ECG of Myocardial Infarction (MI): STEMI vs. NSTEMI
- ECG of Inferior Myocardial Infarction (MI)
- ECG of Anterior Myocardial Infarction (MI)
- Abnormal Q Waves: ECGs of Healed Myocardial Infarction (MI)
- Abnormal T Waves: Differentiating Pericarditis from Myocardial Infarction (MI)
- ECG Case: 67-year-old Diabetic Man with Low Blood Pressure

- ECG Case: 17-year-old Man with Pressure Feeling under Sternum
- ECG of Ventricular Hypertrophy
- ECG of Atrial Enlargement
- ECG Case: 52-year-old Man with Shortness of Breath
- ECG Case: 44-year-old Woman with Shortness of Breath and Fatigue
- Review of Cardiac Conduction System
- Bundle Branch and Fascicular Blocks
- ECG Case: 70-year-old Man with Acute Anterior MI
- Sick Sinus Syndrome and Sinus Exit Block
- First-degree AV Blocks
- Second-degree AV Blocks
- Third-degree AV Blocks
- ECG Case: 88-year-old Man with Syncope
- Supraventricular Arrhythmias: Introduction
- ECG of Atrial Premature Beats
- ECG of Supraventricular Tachycardia
- ECG of Atrial Flutter and Fibrillation
- ECG of Nodale Extra Systoles
- ECG Case: 80-year-old Woman with Palpitations and Shortness of Breath
- Types of Pacemaker
- How to Read a Pacemaker ECG
- Implantable Cardiac Defibrillator (ICD) Pacemaker
- ECG Case: 77-year-old Man with Pacemaker
- ECG of Premature Ventricular Contraction (PVC)
- ECG of Ventricular Tachycardia and Cardiac Arrest
- ECG of Torsades de Pointes
- ECG Case: 40-year-old Woman with 'Extra Heart Beats'
- Effects of Electrolyte Abnormalities on the ECG
- Effects of Drugs on the ECG
- ECG Case: 65-year-old Man with CRF Misses Dialysis

- How to Read an ECG: Conclusion
- Power ECG Case Session

Cardiovascular Cases

- Cardiac Case: 57-year-old Man with Substernal Chest Pain
- Cardiac Case: 62-year-old Woman with Fever and Epigastric Discomfort
- Cardiac Case: 44-year-old Man with Indigestion during Exertion
- Cardiac Case: 46-year-old Woman with Shortness of Breath when Walking
- Cardiac Case: 77-year-old Man with Shortness of Breath and Palpitations
- Cardiac Case: 76-year-old Man with COPD and Sudden Increase in Shortness of Breath
- Cardiac Case: 19-year-old Man with Central Chest Pain Worsening when Breathing
- Cardiac Case: 55-year-old Man with Sudden Anterior Chest Pain Radiating to Back
- Cardiac Case: 82-year-old Man with Syncope
- Cardiac Case: 54-year-old Woman with Breast Cancer and Dyspnea
- Cardiac Case: 45-year-old Man with Alcohol Intake after Minor Traffic Accident
- Cardiac Case: 21-year-old Woman with Fatigue and Shortness of Breath when Exercising
- Cardiac Case: 56-year-old Man with Dyspnea and Ankle Edema
- Cardiac Case: 86-year-old Woman with Shortness of Breath during Annual Checkup
- Cardiac Case: 72-year-old Man with Dyspnea at Rest and Inability to Lie Flat

- Cardiac Case: 18-year-old Woman with Murmur
- Cardiac Case: 68-year-old Woman with Murmur and Abnormal Heart Valve
- Cardiac Case: 24-year-old Man with Asymptomatic Murmur
- Cardiac Case: 67-year-old Woman with Cardiac Arrest
- Cardiac Case: 18-year-old Woman with Fast Heart Beat and Shortness of Breath
- Cardiac Case: 79-year-old Man with Pacemaker and Recent Dental Procedure
- Cardiac Case: 22-year-old Woman with Fever and Ankle Edema after Long-term Heroin Abuse
- Cardiac Case: 61-year-old Man with Substernal Chest Discomfort, Shortness of Breath and Diffuse Sweating
- Cardiac Case: 17-year-old Man with High Blood Pressure
- Cardiac Case: 42-year-old Woman with Joint Discomfort, Low Grade Fever, and Dyspnea
- Cardiac Case: 62-year-old Man with Shortness of Breath and Peripheral Edema
- Cardiac Case: 22-year-old Woman with Leg Edema, Dyspnea and Fatigue
- Cardiac Case: 38-year-old Woman with Shortness of Breath and Inability to Lie Flat after Childbirth
- Vascular Case: 72-year-old Man with Foot Pain and Gangrenous Left Hallux
- Vascular Case: 37-year-old Man with Elevated Blood Pressure after Motor Vehicle Accident

Clinical Neurology

- Acquired Neuromuscular Diseases 26 Videos
- Hereditary Neuromuscular Disorders 12 Videos
- Disorders of the Neuromuscular Junctions 21 Videos
- Peripheral Neuropathies 21 Videos
- Diseases of the Spinal Cord 20Videos
- Diseases of the Motor Neurons 08 Videos
- Multiple Sclerosis (MS) and Inflammatory Disorders of the CNS 08 Videos
- Stroke and Intracranial Hemorrhage 28 Videos
- Seizures and Epilepsy 30 Videos
- Head Trauma 20 Videos
- CNS Infections 24 Videos
- Parkinson Disease and Movement Disorders 14 Videos
- Dementia and Amnestic Conditions 15 Videos
- CNS Tumors 37 Videos
- Sleep Disorders 21 Videos
- Vertigo, Dizziness, and Disorders of Balance 20 Videos
- Headache 24 Videos
- Neuropathic Pain Syndromes 11 Videos
- Neurologic and Psychiatric Emergencies 35 Videos
- Pediatric Neurology 19 Videos

Acquired Neuromuscular Diseases

- Introduction to Myopathy
- Case: 54-year-old Woman with Weakness
- Clinical Approach to Muscle Disorders
- Myopathy and Myositis: Diagnosis
- Evaluation of Muscle Diseases
- Introduction to Inflammatory Myopathies with Case
- Inflammatory Myopathies: Types
- Creatine Kinase Evaluation
- Polymyositis
- Dermatomyositis
- Inclusion Body Myositis
- Necrotizing Autoimmune Myositis
- Overlap Myopathies
- Antibody Assessments – Inflammatory Myopathies
- Management of Inflammatory Myopathies
- Polymyalgia Rheumatica (PMR) – Inflammatory Myalgia
- Introduction to Infectious Myopathies with Case
- HIV-associated Myositis – Infectious Myopathies
- Pathogen Myositis with *Trichinella* – Infectious Myopathies
- Toxic Myopathies with Case
- Hypothyroid and Hyperthyroid Myopathy
- Statin Myopathy
- Corticosteroid Myopathy
- Critical Illness Myopathy and Other Causes for Myopathy
- Rhabdomyolysis
- Other Metabolic Muscle Diseases

Hereditary Neuromuscular Disorders

- Inherited Muscle Disorders: Evaluation
- Inherited Myopathies: Types
- Muscular Dystrophies
- Introduction to Proximal Predominant Muscular Dystrophies
- Case: 6-year-old Boy with Weakness
- X-linked Dystrophinopathies and Duchenne Muscular Dystrophy
- Becker Muscular Dystrophy and Limb-girdle Muscular Dystrophy (LGMD)
- Distal Predominant Muscular Dystrophies
- Other Muscular Dystrophies
- Case: 5-month-old Girl with Weakness
- Evaluation of the Hypotonic Infant
- Congenital Muscular Dystrophy and Congenital Myopathy

Disorders of the Neuromuscular Junctions

- General Approach to Neuromuscular Junction Disorders
- Case: 32-year-old Woman with Weakness
- Physiology of the Neuromuscular Junction
- Neuromuscular Junction Disorders: Clinical Features and Pathophysiology
- Neuromuscular Junction Disorders: Summary
- Case: 32-year-old Woman with Weakness and Sustained Upgaze
- Myasthenia Gravis: Introduction and Clinical Features
- Myasthenia Gravis: Clinical and Serological Tests – Diagnosis
- Myasthenia Gravis: Repetitive Stimulation – Diagnosis

- Myasthenia Gravis: Antibody Testing – Diagnosis
- Myasthenia Gravis: Treatment
- Case: 72-year-old Woman with Weakness
- Botulinum Toxin Toxicity: Overview
- Botulinum Toxin Toxicity: Pathophysiology and Treatment
- Case: 42-year-old Man with Weakness
- Lambert Eaton Myasthenic Syndrome (LEMS): Overview
- Lambert Eaton Myasthenic Syndrome (LEMS): Workup and Testing
- Lambert Eaton Myasthenic Syndrome (LEMS): Pathophysiology and Treatment
- Organophosphate Poisoning
- Transient Neonatal Myasthenia
- Congenital Myasthenic Syndrome (CMS)

Peripheral Neuropathies

- Introduction to Neuropathy Disorders
- Acute Inflammatory Demyelinating Polyneuropathy (AIDP)
- Chronic Inflammatory Demyelinating Polyneuropathy (CIDP)
- Other Non-inflammatory Neuropathies
- Toxic and Metabolic Polyneuropathies

Diseases of the Spinal Cord

- Case: 45-year-old Man with Bilateral Lower Extremity Weakness and Numbness
- Introduction to Spinal Cord
- Myelopathy
- Case: 53-year-old Woman with Progressive Weakness and Balance Difficulty

- How to Approach Spinal Cord Pathology (Macro)
- How to Approach Spinal Cord Pathology (Micro)
- Continuation of Case: 53-year-old Woman with Progressive Weakness and Balance Difficulty
- Case: 58-year-old Woman with Weakness and Neck Pain
- Intradural Extramedullary Myelopathy
- Case: 50-year-old Woman with Lower Extremity Weakness
- Intradural Intramedullary Myelopathy
- Case: 53-year-old Man with Numbness in Lower Extremities
- Myelopathy – Vascular Disorders with Case
- Case: 22-year-old Woman with Back Pain and Autonomic Symptoms
- Myelopathy – Conus Medullaris vs. Cauda Equina
- Case: 45-year-old Man with Lower Extremity Weakness
- Toxic and Metabolic Causes of Myelopathy
- Vitamin B12 Deficiency Myelopathy
- Case: 57-year-old Woman with Leg and Back Pain
- Radiculopathy

Diseases of the Motorm Neurons

- Case: 56-year-old Woman with Left Extremity Weakness
- Introduction to Motor Neurons and Motor/Sensory Pathways
- Upper and Lower Motor Neuron Diseases: Clinical Manifestations
- Upper and Lower Motor Neuron Etiology
- Upper and Lower Motor Neuron Diseases: Diagnosis and Management
- Case: 53-year-old Man with Generalized Weakness
- Upper and Lower Motor Neuron Diseases: Differential Diagnosis
- Amyotrophic Lateral Sclerosis (ALS) and Other Motor Neuron Diseases

Multiple Sclerosis (MS) & Inflammatory Disorders of the CNS

- Introduction to Neuroinflammatory Disorders
- Neuroinflammatory Disorders: Classification
- Overview of CNS Inflammatory Diseases
- Case: 51-year-old with Left Hand Numbness
- Clinically Isolated Syndrome: Clinical Manifestations and Classification
- Clinically Isolated Syndrome: Diagnostics and Treatment
- Acute Disseminated Encephalomyelitis (ADEM)
- Case: 21-year-old Woman with Blurry Vision
- Multiple Sclerosis (MS): Pathophysiology and Clinical Manifestations
- Multiple Sclerosis (MS): Diagnosis and Evolution of Disease
- Multiple Sclerosis (MS): Management
- Neuromyelitis Optica (NMO)
- MOG Ab Disorder
- MS, NMO, MOG Disorder

Stroke: Introduction and Types

- Stroke: Introduction and Types
- Overview of Ischemic and Hemorrhagic Stroke
- Stroke: Pathophysiology
- Case: 45-year-old Man Presenting with a Stroke – Diagnosis
- Clinical Assessment of Stroke
- Clinical Question: Anterior or Posterior Circulation Stroke?
- Clinical Question: Cortical, Subcortical or Brainstem Localization?
- Stroke: Localization

- Case: 45-year-old Man Presenting with a Stroke – Management
- Acute Ischemic Stroke: Management and Evaluation
- Clinical Question: Acute or Mimic Stroke?
- Clinical Question: tPA or Endovascular Therapy?
- NIH Stroke Scale (NIHSS)
- Acute Ischemic Stroke: Major Treatment Types
- Case: 45-year-old Man Presenting with a Stroke
- Stroke: Evaluating Stroke Extension
- Stroke: Work-up and Etiology
- Stroke: Complications
- Management of the Case: 45-year-old Man Presenting with a Stroke
- Stroke: Pharmacological Prevention
- Case: 35-year-old Presenting with Hemiplegia
- Intracranial Hemorrhage: Types and Epidural Hematoma
- Intracranial Hemorrhage: Subdural Hematoma and Subarachnoid Hemorrhage
- Intracranial Hemorrhage: Intraparenchymal, Intraventricular, Hypertensive, and Transformation Hemorrhage
- Intracranial Hemorrhage: Evaluation
- Intracranial Hemorrhage: Management
- Intracranial Hemorrhage: Amyloid Angiopathy, Vascular Lesions, and Neoplasms
- Intracranial Hemorrhage: Evaluation and Summary

Seizures & Epilepsy

- Seizures, Epilepsy, and Spells: Introduction and Differentiation
- Seizures: Types and Classification
- Seizures: Mechanisms
- Seizures: Semiology
- Epilepsy: Diagnosis and Syndromes

- Seizures: Evaluation and Functionality of the EEG
- Seizures: Treatment
- Diagnosis and Evaluation of a Spell with Case
- Review of Seizure Systems
- Differentiating Seizure from Syncope and from Psychogenic Nonepileptic Spells (PNES)
- Evaluation of Seizure-like Episodes
- Case: 45-year-old Man with a Seizure-like Episode
- Seizure: Classification and Focal vs. Generalized Onset
- First-time Seizure: Evaluation, History, and Examination
- Second Seizure: History and Forms of Screening
- Second Seizure: Summary and Precautions
- Case: 57-year-old Man with a History of Epilepsy
- Status Epilepticus: Evaluation, Prognosis, and Classification
- Status Epilepticus: Emergency Treatment, Initial Investigation and Long-term Treatment
- Status Epilepticus: Stages and Pathophysiology
- Status Epilepticus: Treatment and Types
- Case: 13-year-old Boy on Referral from His PCP
- Epilepsy Syndrome: Introduction and Classification
- Idiopathic Generalized Onset and Idiopathic Focal Onset Epilepsies
- Symptomatic Epilepsies
- Case: 57-year-old Woman with Seizure-like Episodes
- Partial Onset Epilepsy: Treatment
- Medication for Focal Onset and Primary Generalized Epilepsy – Seizure Treatment
- Common Seizure Medications – Seizure Treatment
- Top 10 Seizure Treatment Tips with Cases

Head Trauma

- Case: 68-year-old Man with Progressive Altered Mental Status
- Head Trauma: Introduction and Diffuse Axonal Injury
- Head Trauma: Clinical Manifestations and Glasgow Coma Scale
- Head Trauma: Diagnosis and Management
- Traumatic Brain Injury: Introduction
- Traumatic Brain Injury: Diagnosis
- Mild and Sport-related Traumatic Brain Injury
- Traumatic Brain Injury: Chronic Traumatic Encephalopathy
- Traumatic Brain Injury: Management
- Case: 6-year-old Girl Hits Her Head
- Epidural Hematoma: Etiology, Clinical Presentation, and Diagnosis
- Epidural Hematoma: Management
- Case: 68-year-old Man with Progressive Altered Mental Status and Gaze
- Subdural Hematoma: Etiology and Clinical Presentation
- Subdural Hematoma: Diagnosis and Management
- Case: 43-year-old Woman with Altered Mental Status
- Subarachnoid Hemorrhage: Etiology, Clinical Manifestations, and Diagnosis
- Subarachnoid Hemorrhage: Management

CNS Infections

- Bacterial Meningitis: Introduction and Symptoms
- Bacterial Meningitis: Examination
- Bacterial Meningitis: Diagnosis
- Case: 76-year-old Woman with Headache – Follow Up
- Bacterial Meningitis: Treatment
- Viral and Non-bacterial Meningitis

- Case: 61-year-old Man with Headache
- Encephalitis: Introduction and Symptoms
- Encephalitis: Examination
- Other Viral Encephalitis
- Encephalitis: Treatment
- Case: 56-year-old Man with Headache
- Cerebritis and Brain Abscess
- Case: 58-year-old Woman with Headache
- Cryptococcal Meningitis
- Toxoplasmic Meningitis
- Neurocysticercosis: Introduction
- Neurocysticercosis: Life Cycle, Presentation, and Disease Stages
- Neurocysticercosis: Treatment

Parkinson Disease & Movement Disorders

- Introduction to Parkinson Disease
- Idiopathic Parkinson Disease
- Parkinson-Plus Syndromes
- Non-parkinsonian Movement Disorders

Dementia & Amnestic Conditions

- Introduction to Dementing Diseases
- Alzheimer Dementia
- Other Dementias

CNS Tumors

- Brain Tumors: Introduction, Classification, and Diagnostic Evaluation
- Case: 32-year-old-Woman with Bradyphrenia
- Metastatic Brain Tumors: Introduction
- Metastatic Brain Tumors: Surgery – Treatment
- Metastatic Brain Tumors: Radiosurgery – Treatment
- Metastatic Brain Tumors: Chemotherapy – Treatment
- Case: 40-year-old Woman with Headache
- Meningioma: Introduction
- Meningioma: Clinical Presentation and Evaluation
- Meningioma: Treatment
- Case: 67-year-old Woman with Headaches
- Pituitary Tumors: Introduction
- Pituitary Tumors: Clinical Presentation
- Pituitary Tumors: Evaluation and Imaging
- Pituitary Tumors: Treatment
- Case: 49-year-old Man with Headache
- Glioma: Introduction and Clinical Presentation
- Glioma: Grading with MRI and Contrast Enhancement
- Glioma: Grading with Tissue Sample
- Glioma: Genetic Risk Assessment
- Glioma: Treatment
- Case: 21-year-old Man with Pain
- Neurofibromatosis Type 1: Introduction
- Knudson's Two-Hit Hypothesis of Tumor Formation
- Neurofibromatosis Type 1: Diagnosing Criteria
- Neurofibromatosis Type 1: Clinical Presentation
- Neurofibromatosis Type 1: Treatment
- Case: 42-year-old Woman with Loss of Hearing

- Neurofibromatosis Type 2: Introduction
- Neurofibromatosis Type 2: Diagnosing Criteria
- Neurofibromatosis Type 2: Clinical Presentation
- Neurofibromatosis Type 2: Treatment
- Case: 2.5-month-old Infant with Spasms
- Tuberous Sclerosis: Introduction
- Tuberous Sclerosis: Diagnosing Criteria
- Tuberous Sclerosis: Clinical Presentation
- Tuberous Sclerosis: Treatment

Sleep Disorders

- Introduction to Sleep
- Circadian Rhythm
- Stages of Sleep
- Case: 45-year-old with Difficulty Sleeping
- Insomnia: Classification and Pathophysiology
- Insomnia: Diagnosis
- Insomnia: Management
- Case: 54-year-old with Excessive Daytime Sleepiness
- Circadian Rhythm Sleep-wake Disorders and Delayed Sleep-wake Phase Disorder
- Sleep-wake Phase Disorder: Advance, Irregular, and Non-24-hour
- Sleep-wake Phase Disorder: Shift Work Disorder and Jet Lag
- Sleep-wake Phase Disorder: Management
- Case: 39-year-old Acting Out Dreams
- Introduction to Parasomnias
- NREM-related Parasomnias
- REM-related Parasomnias and Management of Parasomnias
- Case: 12-year-old with Hallucinations

- Introduction to Narcolepsy
- Narcolepsy: Epidemiology and Clinical Features
- Narcolepsy: Diagnosis
- Narcolepsy: Management

Vertigo, Dizziness, & Disorders of Balance

- Case: 34-year-old Woman with Severe Dizziness
- Dizziness: Signs and Symptoms
- Introduction to Nonspecific Dizziness
- Dysequilibrium and Cerebellar Diseases
- Case: 67-year-old Woman with Gait Dysfunction
- Cerebellum: Lobes – Anatomy Review
- Case: 14-year-old Girl with Dizziness
- Cerebellum: Afferent and Efferent Pathways – Anatomy Review
- Case: 53-year-old Man with Ataxia
- Cerebellum: Nuclei – Anatomy Review
- Case: 68-year-old Man Presenting with Fainting Episodes
- Syncope: Definition, Etiology, and Causes
- Neurally Mediated Syncope: Definition, Pathophysiology, and Classification
- Syncope: Evaluation, Treatment, and Management
- Case: 34-year-old with Dizziness
- Review of the Vestibular System and Evaluation of Vertigo
- Vertigo: Types
- Acute Vestibular Syndrome: Causes and Differentiation
- Exam Techniques: Head Impulse Test (HIT), Nystagmus, and Test of Skew
- HINTS of INFARCT • Exam Techniques: Head Impulse Test (HIT), Nystagmus, and Test of Skew

- HINTS of INFARCT

Headache

- Introduction to Headaches: Groups and 3-Step-Evaluation System
- Step 1: Primary and Secondary Headaches and Types of Headaches
- Step 2: Options for Diagnostic Testing and Clues to Severe Disease
- Step 3: Treatment of Headaches
- Case: 45-year-old Woman with Headache
- Thunderclap Headache: Overview, Evaluation, and Management
- Case: 67-year-old Woman with History of Migraines
- Headache with Visual Disturbances
- Case: 68-year-old Man with Squamous Cell Carcinoma
- Neuralgiform Headaches
- Case: 57-year-old Woman with Headache when Sitting Up
- Low-pressure Headache
- Case: 38-year-old Obese Woman with Headache
- High-pressure Headache
- Case: 30-year-old Woman with Episodic Headache
- Chronic, Recurrent, and Episodic Headaches
- Migraine: Aura, Triggers, Evaluation, and Treatment
- Migraine: Prophylaxis and Medications
- Case: 25-year-old Man with Cluster of Headaches
- Trigeminal Autonomic Cephalalgias (TACs)
- Cluster Headaches
- Paroxysmal Hemicrania
- SUNCT and SUNA
- Hemicrania Continua

Neuropathic Pain Syndromes

- Neuropathic Pain: Esthesia, Algesia, Pathia, and Dynia
- Neuropathic Pain: Understanding Reflex Arcs
- Neuropathic Pain: Clues to Locate the Lesion (CNS or PNS)
- Neuropathic Pain: Locating a Lesion in the PNS
- Case: 53-year-old Man with Intense Hip Pain
- Case: 31-year-old Woman with Pruritic Vesicles
- Diabetic Polyneuropathy
- Chemotherapy-induced Polyneuropathy
- Case: 43-year-old Woman with Sharp Pain on the Right Side of Her Face
- Neuropathic Pain: Thalamic Pain Syndrome
- Neuropathic Pain: Treatment

Neurologic & Psychiatric Emergencies

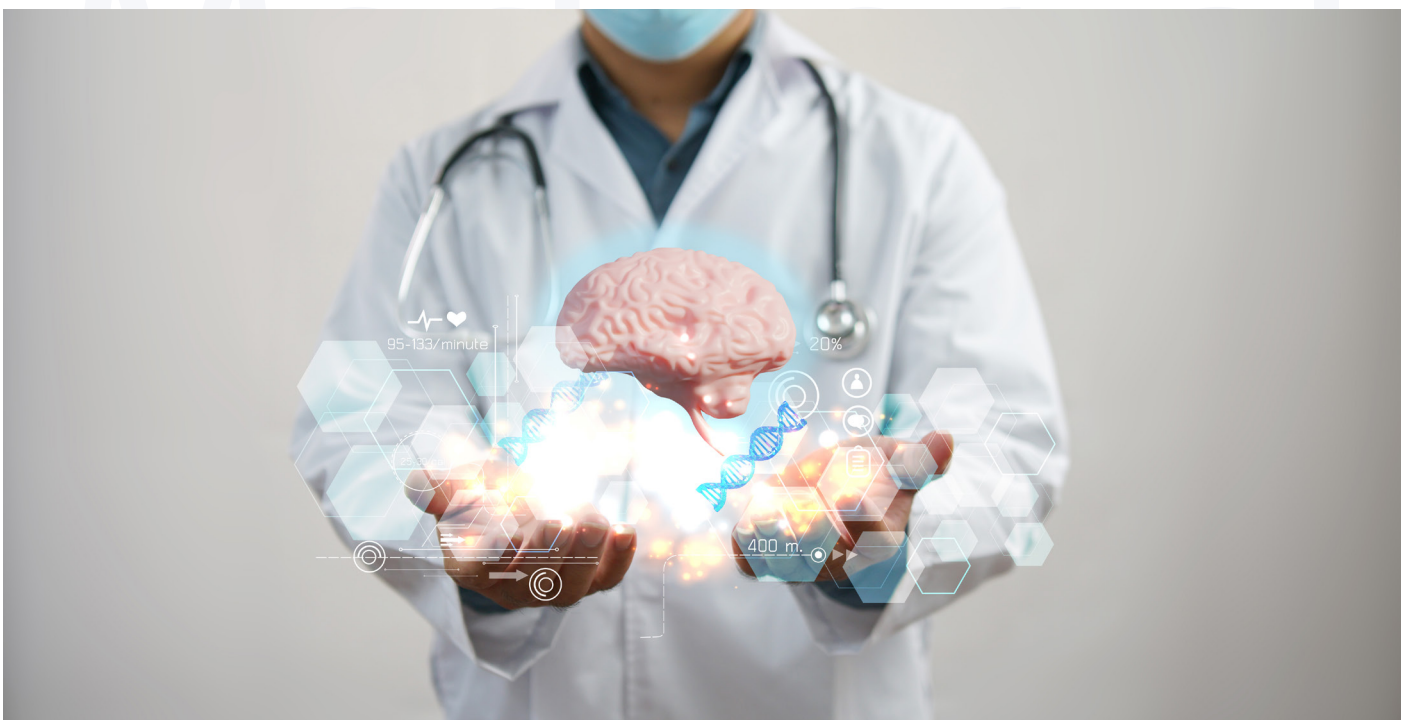- Altered Mental Status (AMS – Emergency Medicine)
- Altered Mental Status (AMS): Common Causes
- Altered Mental Status (AMS): First steps
- Altered Mental Status (AMS): History
- Altered Mental Status (AMS): Management
- Headache (Emergency Medicine)
- Migraine: Presentation & Diagnosis
- Migraine: Management
- Cluster Headache (Emergency Medicine)
- Secondary Headache (Emergency Medicine)
- Acute Ischemic Stroke (AIS – Emergency Medicine)
- Acute Ischemic Stroke (AIS): Signs & Symptoms

- Acute Ischemic Stroke (AIS): Examination
- Acute Ischemic Stroke (AIS): Diagnosis
- Acute Ischemic Stroke (AIS): Management
- Spontaneous Intracerebral Hemorrhage (ICH – Emergency Medicine)
- Spontaneous Intracerebral Hemorrhage (ICH): Examination & Diagnosis
- Spontaneous Intracerebral Hemorrhage (ICH): Management
- Subarachnoid Hemorrhage (SAH – Emergency Medicine)
- Subarachnoid Hemorrhage (SAH): Diagnosis
- Subarachnoid Hemorrhage (SAH): Management
- Seizures (Emergency Medicine)
- Seizures: Pathophysiology
- Seizure: Examination
- Seizure: Diagnosis
- Seizure: Management
- Meningitis and Encephalitis (Emergency Medicine)
- Meningitis and Encephalitis: Examination
- Meningitis and Encephalitis: Diagnosis
- Meningitis and Encephalitis: Management & Prophylaxis
- Suicidal Patients (Emergency Medicine)
- Methods of Suicide
- Suicidal Patients: Diagnosis
- Suicidal Patients: Management
- Suicidal Patients: Documentation and Disposition

Pediatric Neurology

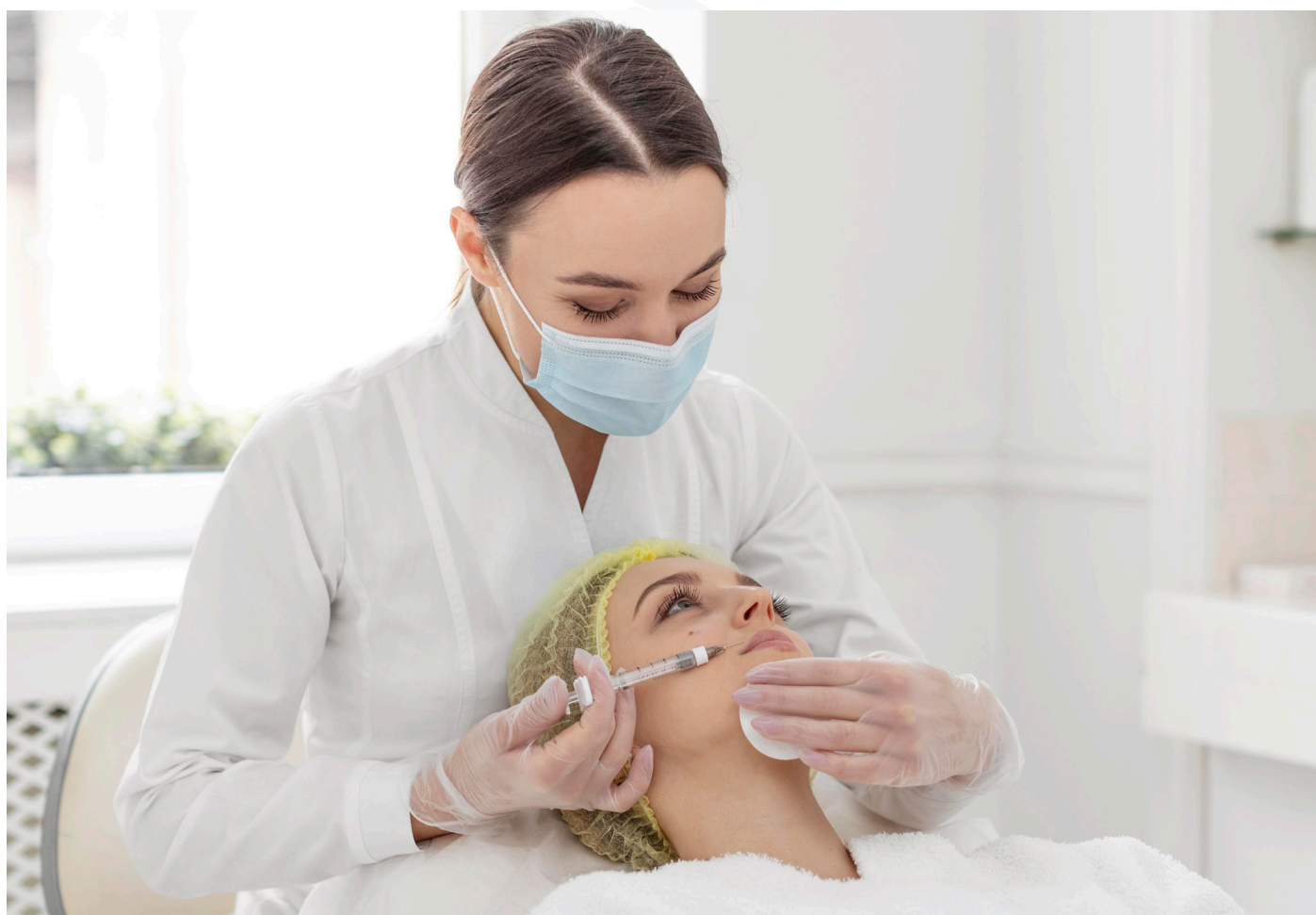- Seizures in Children: Introduction
- Status Epilepticus: Management
- Generalized Seizure in Children
- Febrile Seizure

- Ataxia in Children
- Migraines and Headaches in Children
- Secondary Headache in Children
- Guillan-Barré Syndrome (GBS) and Acute Disseminated Encephalomyelitis (ADEM)
- Muscular Dystrophy in Children
- Spinal Muscular Atrophy (SMA) in Children
- Infant Botulism
- Myasthenia Gravis in Children
- Cerebral Palsy (CP)
- Intellectual Disability in Children
- Tics and Tourettes in Children
- Tuberous Sclerosis in Children
- Neurofibromatosis (NF) and Sturge Weber Syndrome
- Increased Intracranial Pressure (ICP), Hydrocephalus & Dandy-Walker Variant (DWV)
- Arnold-Chiari Malformations and Craniosynostosis



Dermatology

- Allergic and Immune-mediated Skin Disorders 28 Videos
- Neoplasms of the Skin 08 Videos
- Skin Infections 21 Videos
- Miscellaneous Skin Disorders 10 Videos
- Inflammatory Skin Diseases 23 Videos
- Infectious Skin Diseases 12 Videos
- Other Skin Diseases 03 Videos
- Pediatric Dermatology 11 Videos



Allergic and Immune-Mediated Skin Disorders

- Derma Case: 71-year-old Woman with a Progressive Skin Rash
- Anatomy Review: Skin
- Stevens-Johnson Syndrome
- Porphyria Cutanea Tarda
- Pemphigus Vulgaris
- Staphylococcal Scalded Skin Syndrome
- Bullous Pemphigoid
- Quick Review: Bullous Diseases
- Derma Case: 52-year-old Man with Fever, Muscle Aches, and Rash
- Pemphigus Vulgaris (Review) and Staphylococcal Toxic Shock Syndrome
- Erythema Multiforme, Stevens-Johnson Syndrome, and Toxic Epidermal Necrolysis
- Non-immune Mediated Cutaneous Drug Reactions
- Immune-mediated Cutaneous Drug Reactions: Exanthemous Reactions
- Urticaria and Angioedema
- Drug Hypersensitivity Syndrome (DHS) and DRESS
- Quick Review: Cutaneous Drug Reactions
- Derma Case: 52-year-old Woman with Fever, Arthralgias, and Painful Bumps
- Polyarteritis Nodosa vs. Erythema Nodosum
- Quick Review: Erythema Nodosum
- Derma Case: 18-year-old Woman with an Intensely Pruritic Rash
- Seborrheic Dermatitis, Allergic and Irritant Contact Dermatitis
- Atopic Dermatitis (Eczema)
- Derma Case: 36-year-old Woman with Eczema
- Derma Case: 12-year-old Girl with an Intensely Pruritic Rash

- Quick Review: Dermatitis
- Derma Case: 33-year-old Man with Rash on Elbows and Knees
- Psoriasis
- Quick Review: Psoriasis

Neoplasms of the Skin

- Derma Case: 38-year-old Woman with a Mole on Her Left Leg
- Tinea Corporis (Ring Worm) and Seborrheic Keratosis
- Kaposi's Sarcoma
- Melanoma vs. Benign Melanocytic Nevus
- Derma Case: 58-year-old Man with a Lesion on the Tip of His Nose
- Squamous Cell Carcinoma (SCC) vs. Basal Cell Carcinoma (BCC)
- Derma Case: 69-year-old Man with PMHx of CAD and Dyslipidemia
- Quick Review: Malignant Skin Lesions

Skin Infections

- Derma Case: 11-year-old Healthy Girl with Rash
- Molluscum Contagiosum
- Derma Case: 23-year-old Man with Bumps on His Penis
- Acrochordon (Skin Tag)
- Human Papilloma Virus (HPV) and Condylomata Acuminata
- Herpes Simplex Virus and Shingles
- Quick Review: Viral Skin Diseases
- Derma Case: 20-year-old Man with an Itchy Circular Rash
- Pityriasis Rosea
- Tinea Infections: Tinea Corporis and Tinea Versicolor
- Candida Intertrigo and Candida Albicans
- Impetigo
- Tinea Infections: Management

Miscellaneous Skin Disorders

- Derma Case: 41-year-old Woman with Facial Rash
- Acne Vulgaris
- Dermatomyositis and Seborrheic Dermatitis
- Acne Rosacea
- Systemic Lupus Erythematosus (SLE)
- Derma Case: 24-year-old Woman with Chronic Pain in Axillae
- Quick Review: Acne
- Review: Life Cycle of a Hair Follicle
- Derma Case: 57-year-old Woman with Hypertension and Hair Loss
- Quick Review: Alopecia

Inflammatory Skin Diseases

- General Terminology
- Other General Dermatologic Terminologies
- Acne Vulgaris
- Rosacea
- Seborrheic Dermatitis
- Atopic Dermatitis
- Ichthyosis Vulgaris
- Allergic Contact Dermatitis
- Lichen Simplex Chronicus (LSC)
- Lichen Planus
- Hives (Urticaria)
- Angioedema
- Alopecia Areata (AA)
- Psoriasis
- Pityriasis Rosea

- Morphea
- Erythema Nodosum
- Erythema Multiforme
- Pemphigus Vulgaris
- Bullous Pemphigoid
- Immunofluorescence Diagnosis in Vesiculobullous Dermatitis
- Nikolsky's Sign
- Lupus Erythematosus

Pediatric Dermatology

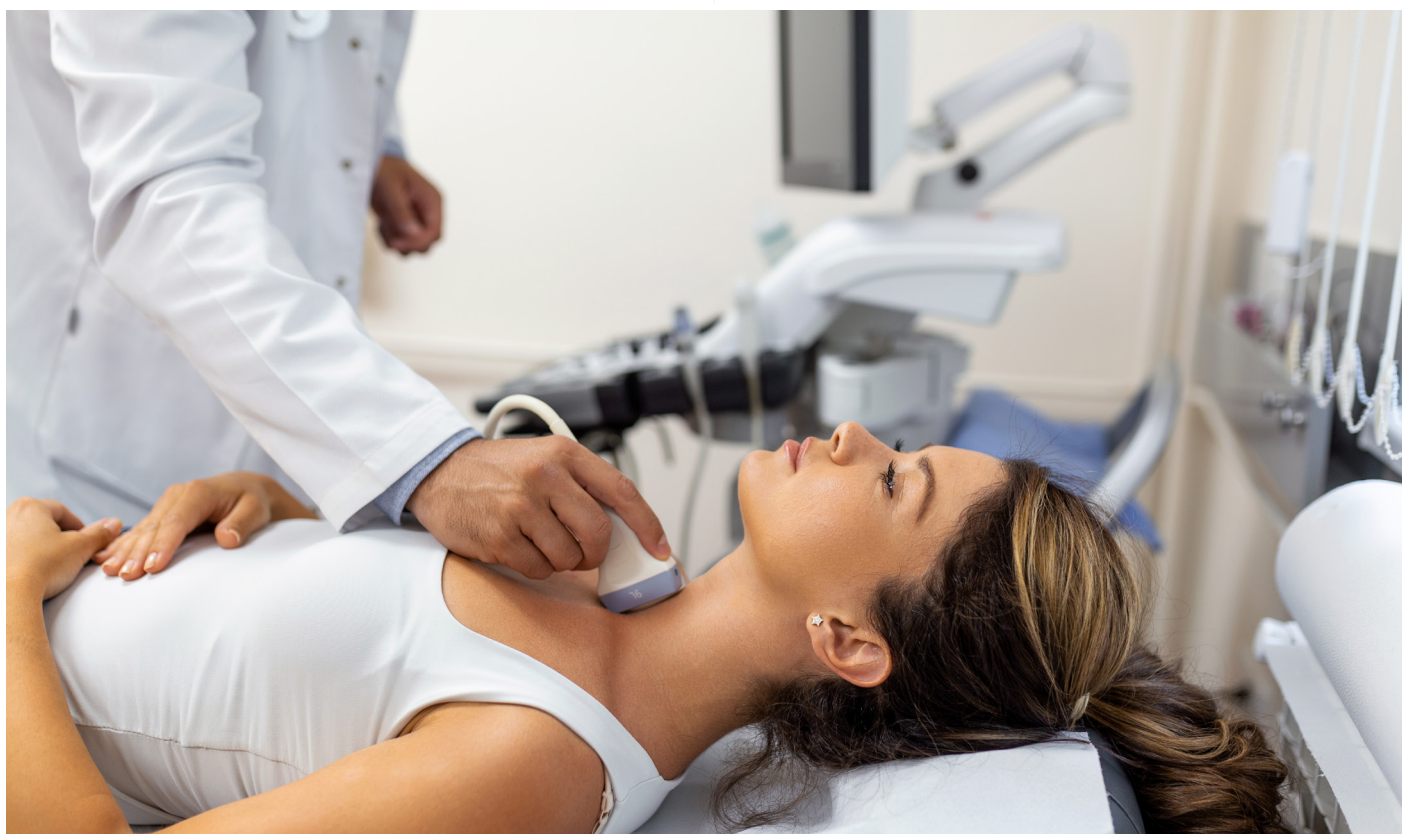
- Eczema in Children
- Seborrheic Dermatitis, Psoriasis and Impetigo in Children
- Erythema Multiforme and Stevens-Johnson Syndrome (SJS) in Children
- Serum Sickness in Children
- Drug Reaction with Eosinophilia and Systemic Symptoms (DRESS)
- Hemangioma
- Nevus (Moles) in Children
- Scabies, Head Lice (Pediculosis Capitis) and Tinea Corporis (Ringworm) in Children
- Pityriasis Rosea in Children
- Warts (Verruca Vulgaris) and Molluscum Contagiosum in Children
- Hair Loss in Children: Alopecia Areata, Nevus Sebaceus, Traction Alopecia & Trichotillomania (TTM)

Other Skin Diseases

- Melasma (Chloasma)
- Vitiligo
- Albinism (Achromasia)

Endocrinology

- | | |
|--|-----------|
| • Thyroid Disorders | 15 Videos |
| • Pituitary and Hypothalamic Disorders | 14 Videos |
| • Adrenal Gland Disorders | 06 Videos |
| • Diabetes Mellitus | 27 Videos |
| • Metabolic Bone Disorders | 12 Videos |
| • Reproductive Endocrine Disorders | 11 Videos |
| • Pediatric Endocrinology | 26 Videos |



Thyroid Disorders

- Review of Thyroid Physiology
- Thyroid Case: 38-year-old Woman with Insomnia, Anxiety & Hair Loss
- Hyperthyroidism and Thyrotoxicosis
- Thyroid Storm with Case
- Graves Disease
- Types of Thyroiditis with Case
- Toxic Adenoma and Multinodular Goiter with Case
- Hyperthyroidism – Summary
- Thyroid Nodules
- Thyroid Cancer with Case
- Thyroid Case: 52-year-old Woman with Weight Gain, Fatigue and Poor Concentration
- Hashimoto's Thyroiditis and Subclinical Hypothyroidism
- Euthyroid Sick Syndrome with Case

Pituitary and Hypothalamic Disorders

- Review of Hypothalamic and Pituitary Physiology
- Pituitary Case: 54-year-old Man with Fatigue and Joint Pain
- Acromegaly
- Pituitary Case: 28-year-old Woman with Amenorrhea and Nipple Discharge
- Hyperprolactinemia
- Pituitary Case: 53-year-old Man after Transsphenoidal Resection of Pituitary Adenoma
- Syndrome of Inappropriate ADH (SIADH)

- Pituitary Case: 48-year-old Woman with Weight Gain, Easy Bruising, & Hypertension
- Cushing Syndrome & Cushing Disease
- Summary: Pituitary Hormone Excess
- Pituitary Case: 51-year-old Man with Severe Headache
- Hypothalamic and Pituitary Hormone Deficiency
- Pituitary Case: 28-year-old Woman with Excessive Thirst & Urination
- Diabetes Insipidus and Pituitary Tumors

Adrenal Gland Disorders

- Review of Adrenal Excess & Adrenal Deficiency
- Adrenal Case: 25-year-old Man with Severe Pulsatile Headache
- Pheochromocytoma
- Adrenal Case: 38-year-old Man with Hypertension
- Primary Hyperaldosteronism
- Adrenal Case: 68-year-old Man with Nausea, Lightheadedness, Back and Abdominal Pain

Diabetes Mellitus

- Types of Diabetes
- Diabetic Case: 9-year-old Girl with Thirst, Weight Loss, and Frequent Urination
- Type 1 Diabetes Mellitus (DM)
- Honeymoon Phase with Case
- Diabetic Case: 47-year-old Woman with Pain on Urination, Frequent Urination, and Urine Urgency
- Diabetic Case: 61-year-old Man with Weight Gain
- Prediabetes

- Diabetic Case: 36-year-old Primigravid Woman for Antenatal Care
- Gestational Diabetes
- Type 2 Diabetes Mellitus: Patient Education and Self-monitoring of Blood Glucose
- Type 2 Diabetes Mellitus: Hemoglobin A1c (HbA1c) Monitoring and Non-pharmacologic Approaches
- Bariatric Surgery with Case
- Type 2 Diabetes Mellitus: Rational Management
- Type 1 Diabetes Management with Case
- Diabetic Case: 19-year-old Man with Type 1 DM
- Diabetic Case: 75-year-old Man on Insulin Therapy
- Diabetic Case: 49-year-old Man with Elevated HbA1c
- Non-insulin Diabetes Mellitus Medications with Case
- Basal-bolus Insulin Therapy with Case
- Diabetic Ketoacidosis with Case
- Hyperglycemic Hyperosmolar Syndrome (HHS) with Case
- Comparing Hyperglycemic Hyperosmolar Syndrome (HHS) and Diabetic Ketoacidosis (DKA)
- Diabetes Mellitus: Chronic Complications
- Diabetic Neuropathy with Case
- Diabetic Foot Ulcers with Case
- Hypoglycemia with Case
- Insulinoma (Whipple's Triad) with Case

Metabolic Bone Disorders

- Hypercalcemia and Review of Calcium Homeostasis
- Bone Metabolism Case: 68-year-old Woman with High Serum Calcium Level
- Primary Hyperparathyroidism

- Bone Metabolism Case: 71-year-old Man with Shortness of Breath
- Hypercalcemia: Types and Management
- Hypocalcemia: Causes and Clinical Features
- Iatrogenic Hypoparathyroidism with Case
- Multiple Endocrine Neoplasia (MEN) with Case
- Hypocalcemia: Management
- Osteoporosis with Case
- Osteomalacia with Case
- Paget's Disease with Case

Reproductive Endocrine Disorders

- Reproductive Endocrinology: Course Overview
- Reproductive Case: 17-year-old Woman with Absence of Menarche
- Primary and Secondary Amenorrhea
- Reproductive Case: 34-year-old Woman with Hirsutism
- Polycystic Ovary Syndrome (PCOS)
- Female Infertility
- Male Hypogonadism with Case
- Male Infertility
- Gynecomastia with Case: 6-day-old Girl with Vomiting and Poor Feeding
- Congenital Adrenal Hyperplasia (CAH)

Pediatric Endocrinology

- Tracking Growth in Children
- Understanding Short Stature in Children
- Growth Delay: Diagnosis & Management
- Normal Puberty in Children

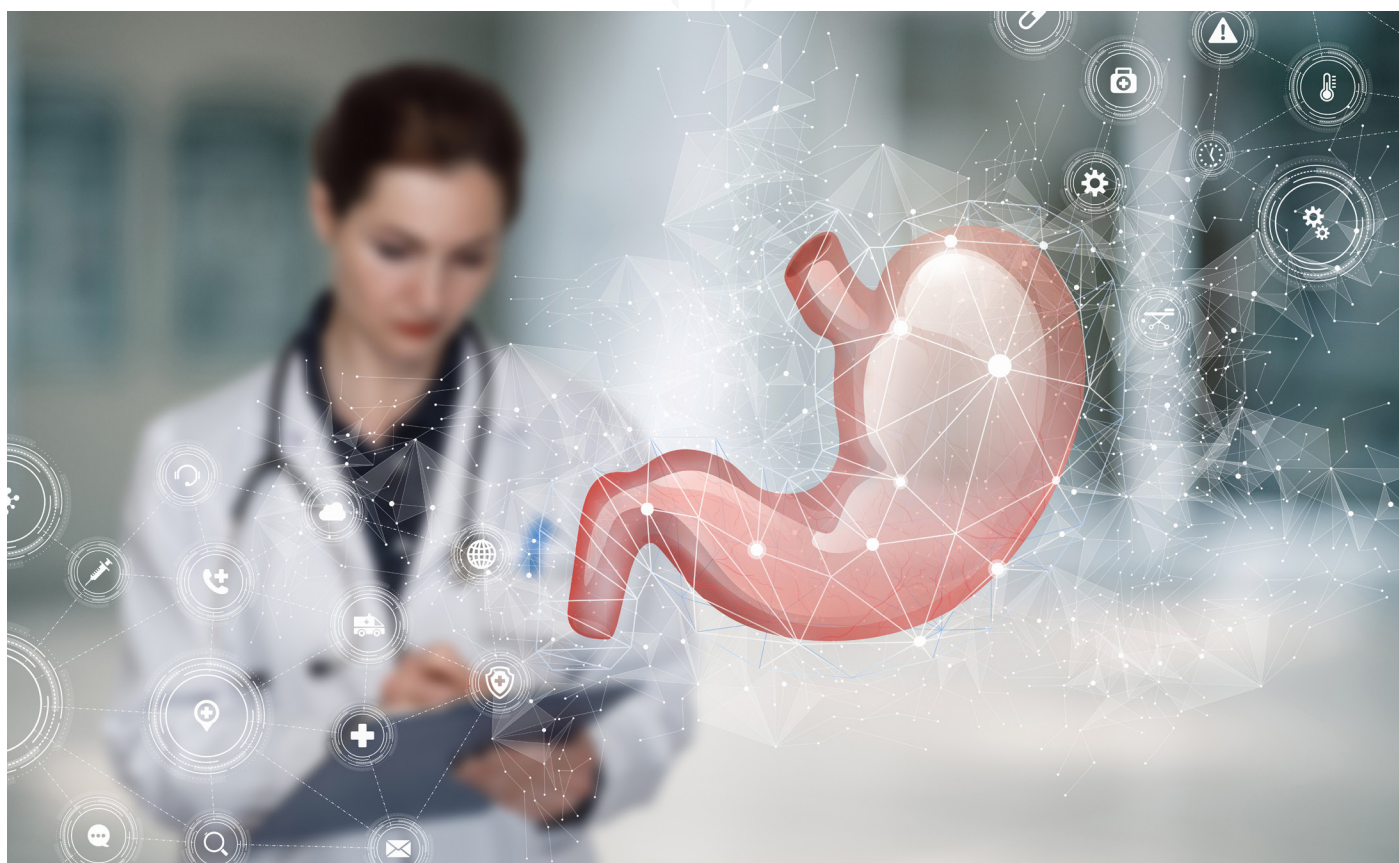- Precocious Puberty in Children
- Delayed Puberty in Children
- Inborn Errors of Metabolism: Metabolic Pathways
- Disorders of Carbohydrate Metabolism
- Disorders of Amino Acid Metabolism
- Defects of Fatty Acid Oxidation
- Urea Cycle Disorders
- Type 1 Diabetes (Juvenile Diabetes): Basics
- Type 1 Diabetes (Juvenile Diabetes): Typical Presentation
- Type 1 Diabetes (Juvenile Diabetes): Diagnosis
- Type 1 Diabetes (Juvenile Diabetes): Management
- Type 2 Diabetes (Adult Onset Diabetes)
- Diabetes Insipidus (DI) in Children
- SIADH (Syndrome of Inappropriate Antidiuretic Hormone Secretion) in Children
- Hyperthyroidism in Children
- Hypothyroidism in Children
- Congenital Adrenal Hyperplasia (CAH) in Children
- Cushing's Syndrome in Children
- Adrenal Insufficiency (Addison's Disease) in Children

Gastroenterology

- Gastroenterology
- Pediatric Gastroenterology

67 Videos

33 Videos



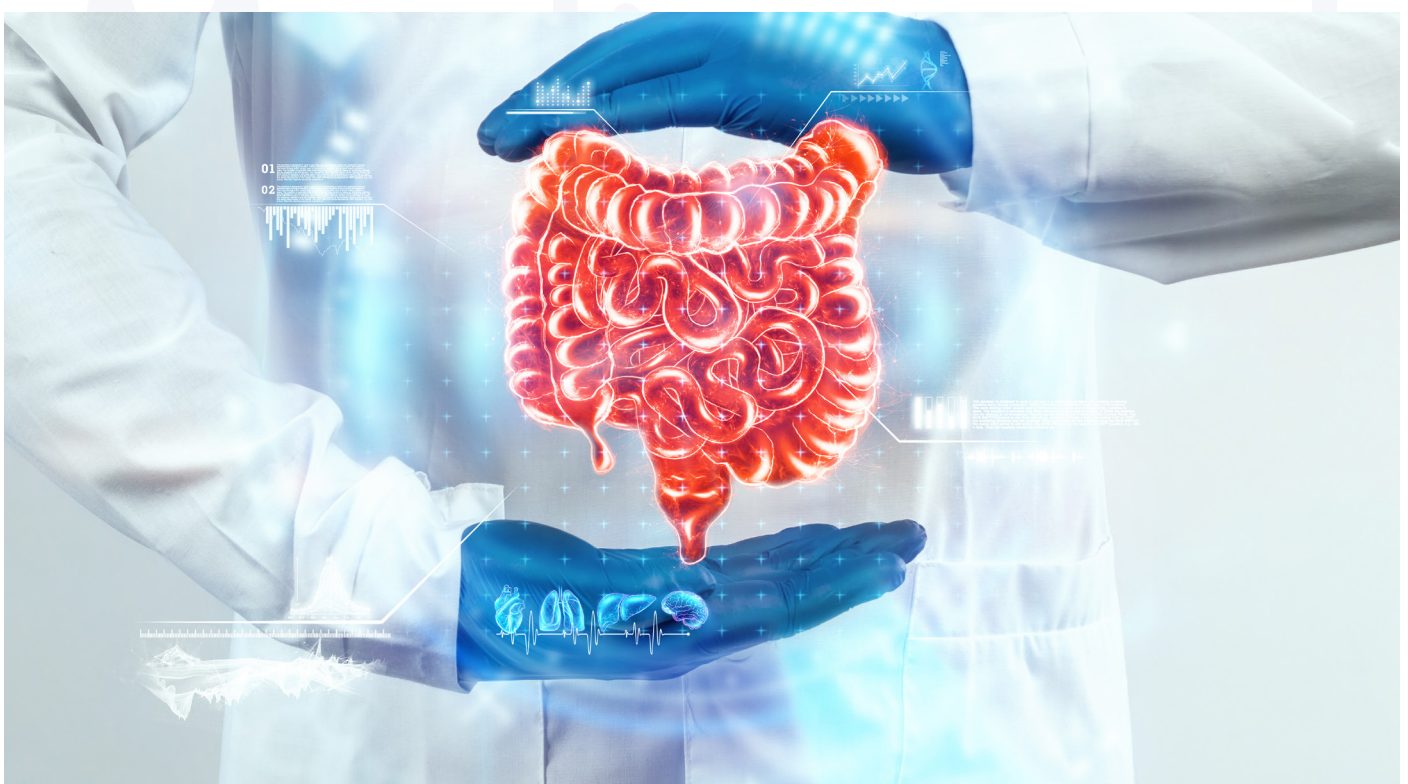
Gastroenterology

- Approach to Patients with GI Symptoms
- Disorders of the Esophagus and the Stomach
- Disorders of the Small and Large Intestines
- Disorders of the Hepatobiliary Tract
- Disorders of the Pancreas
- Disorders of the Peritoneum

Pediatric Gastroenterology

- Approach to Vomiting
- Pediatric Diarrhea: Pathology
- Pediatric Diarrhea: History & Physical Exam
- Pediatric Diarrhea: Lab Work & Imaging
- Conjugated Hyperbilirubinemia
- Alagille Syndrome
- Biliary Atresia
- Pediatric Choledochal Cysts
- Appendicitis in Children
- Pediatric Meckel's Diverticulum
- Intussusception in Children
- Pancreatitis in Children: Pathology
- Pancreatitis in Children: Signs, Symptoms, Diagnosis & Management
- Pediatric Cholecystitis (Inflammation of the Gallbladder)
- Failure to Thrive (FTT): Pathology
- Failure to Thrive (FTT): History & Physical Exam
- Failure to Thrive (FTT): Management
- Constipation in Children: Pathology & Clinical Presentation
- Constipation in Children: Diagnosis & Management

- Hirschsprung's Disease (Congenital Megacolon)
- Congenital Hypertrophic Pyloric Stenosis
- Duodenal Atresia in Children
- Intestinal Malrotation
- Gastroesophageal Reflux Disease (GERD): Pathology, Signs & Symptoms
- Gastroesophageal Reflux Disease (GERD): Diagnosis & Management
- Milk Protein Allergy in Children (Cow's Milk Protein Intolerance, CMPA)
- Celiac Disease in Children
- Pediatric Inflammatory Bowel Disease (IBD): Basics
- Pediatric Inflammatory Bowel Disease (IBD): Diagnosis
- Pediatric Inflammatory Bowel Disease (IBD): Management
- Fluid Replacement Therapy (FTP) in Children: Basics
- Fluid Replacement Therapy (FTP) in Children: Diagnosis
- Fluid Replacement Therapy (FTP) in Children: Management



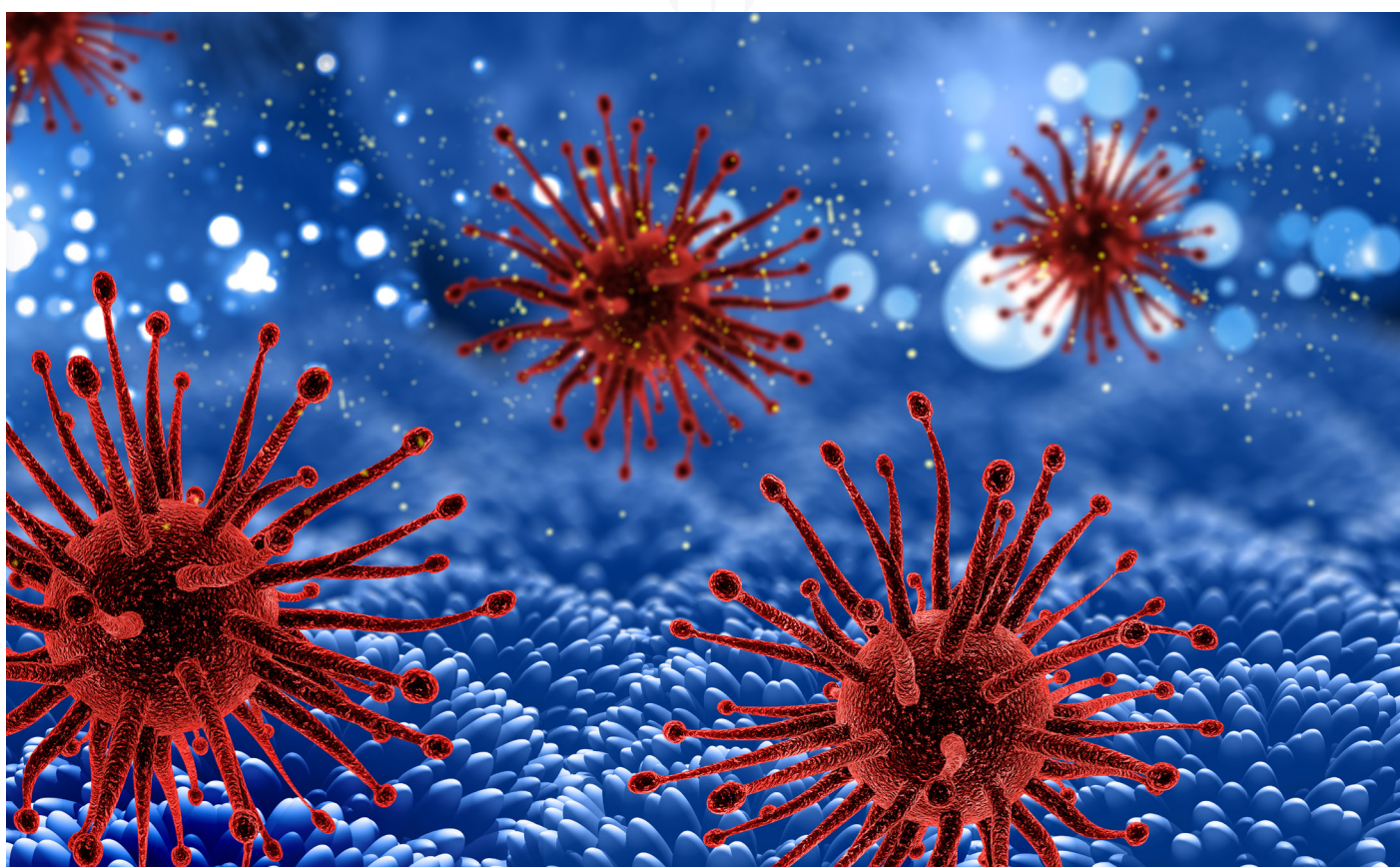
Haematology

Hematologic Disorders

- Anemia and Iron Deficiency – Red Cell Disorders
- Thalassemia – Red Cell Disorders
- Types of Anemia – Red Cell Disorders
- Polycythemia – Red Cell Disorders
- Types – Leukemia
- Acute Leukemia – Leukemia
- Chronic Leukemia – Leukemia
- Hodgkin Lymphoma – Lymphoma
- Non-hodgkin Lymphomas – Lymphoma
- Other Types – Lymphoma
- Myelodysplasia – Hematopoietic Malignancies and Aplastic Anemia
- Myeloproliferative Disease – Non-malignant conditions and Multiple Myeloma
- Aplastic Anemia – Hematopoietic Malignancies and Aplastic Anemia
- Hemostasis – Bleeding Disorders
- Other Forms – Bleeding Disorders
- Thrombosis – Thrombosis and Anti-Thrombotic Therapy
- Anticoagulant Drugs – Thrombosis and Anti-Thrombotic Therapy

Infectious Diseases

- | | |
|---|-----------|
| • CNS Infection—Infectious Diseases | 17 Videos |
| • Cardiovascular Infections | 15 Videos |
| • Upper Respiratory Infections | 17 Videos |
| • Gastrointestinal Infections | 15 Videos |
| • Genital and Sexually Transmitted Infections | 29 Videos |
| • Urinary Tract Infections | 06 Videos |



CNS Infection - Infectious Diseases

- Bacterial Meningitis: Definition
- Bacterial Meningitis: Signs/Symptoms in Newborns & Younger Children
- Neisseria Meningitidis (Meningococcus): Signs & Symptoms
- Bacterial Meningitis: Diagnosis & CSF Findings
- Bacterial Meningitis: Management & Empirical Treatment

When Gram's Stain (-)

- Bacterial Meningitis: Prognosis
- Bacterial Meningitis: Etiology & MCV-4 Meningococcal Vaccine
- Encephalitis: Definition and Etiology
- Encephalitis: Vector-borne Viruses
- Encephalitis: Signs & Symptoms
- Encephalitis: Diagnosis
- Encephalitis: Supportive Management
- Brain Abscess: Etiology
- Brain Abscess: Pathology
- Brain Abscess: Signs & Symptoms
- Brain Abscess: Diagnosis
- Brain Abscess: Initial Management

Infectious Diseases - Pediatric Nursing

- Varicella: Etiology and Pathology (Pediatric Nursing)
- Varicella: Signs and Diagnosis (Pediatric Nursing)
- Varicella: Management and Complications (Pediatric Nursing)
- Diphtheria: Etiology and Pathology (Pediatric Nursing)

- Diphtheria: Signs and Diagnosis (Pediatric Nursing)
- Diphtheria: Management and Complications (Pediatric Nursing)
- Erythema Infectiosum – Fifth Disease (Pediatric Nursing)
- Roseola (Pediatric Nursing)
- Measles: Etiology and Pathology (Pediatric Nursing)
- Measles: Signs, Exam, and Diagnosis (Pediatric Nursing)
- Measles: Management and Complications (Pediatric Nursing)
- Mumps: Pathology and Etiology (Pediatric Nursing)
- Mumps: Signs, Exam, and Diagnosis (Pediatric Nursing)
- Mumps: Management and Complications (Pediatric Nursing)
- Rubella: Pathology and Etiology (Pediatric Nursing)
- Rubella: Signs, Exam, and Diagnosis (Pediatric Nursing)
- Rubella: Management and Complications (Pediatric Nursing)
- Viral vs. Bacterial Conjunctivitis (Pediatric Nursing)
- Ophthalmia Neonatorum (Pediatric Nursing)
- Allergic vs. Irritant Conjunctivitis (Pediatric Nursing)
- Conjunctivitis: Exam and Diagnosis (Pediatric Nursing)
- Conjunctivitis: Management and Complications (Pediatric Nursing)
- Giardia: Etiology and Pathology (Pediatric Nursing)
- Giardia: Signs, Exam, and Diagnosis (Pediatric Nursing)
- Giardia: Management and Complications (Pediatric Nursing)
- Pinworms: Etiology and Pathology (Pediatric Nursing)
- Pinworms: Signs and Management (Pediatric Nursing)
- Infectious Diseases: In a Nutshell (Pediatric Nursing)
- Pediatric Immunizations (Nursing)
- Sepsis: Pediatric Sepsis (Nursing)

Infectious Skin Diseases

- Folliculitis
- Verruca (Plantar Wart)
- Herpes Zoster (Shingles)
- Primary Varicella (Chickenpox) and Candidiasis (Yeast Infection)
- Erysipelas and Molluscum Contagiosum
- Herpes Simplex (HSV)
- Impetigo (School Sores) and Staph Scalded Skin Syndrome (SSSS)
- Tinea Infections (Ringworm): Tinea Corporis & Tinea Capitis
- Onychomycosis (Nail fungus) and Scabies (Sarcoptic Mange)
- Syphilis
- Erythema Migrans (Lyme Disease) and Erythema Infectiosum (Fifth Disease)
- Toxic Shock Syndrome and Necrotizing Fasciitis (Flesh-Eating Disease)

Pharmacology

- Pharmacokinetics and Pharmacodynamics
- ANS - Pharmacology
- CNS - Pharmacology
- Toxicology
- Cardiovascular Pharmacology
- Pharmacology of Blood Coagulation
- Endocrine Pharmacology
- Reproductive Pharmacology
- Inflammation Pharmacology
- Respiratory Pharmacology
- Gastrointestinal Pharmacology
- Antimicrobial Pharmacology
- Topical Medications

Nephrology

Nephrology

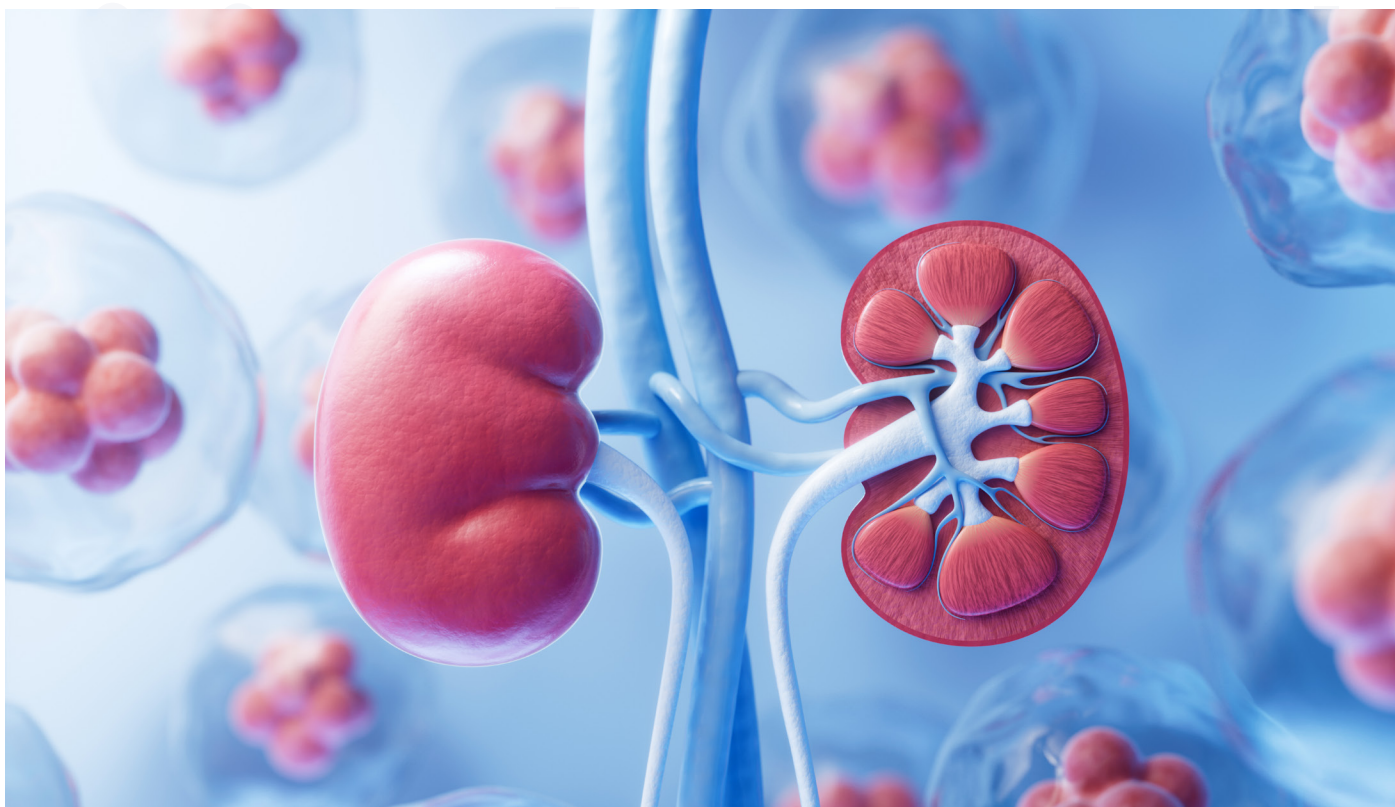124 Videos

Pediatric Nephrology & Urology

015 Videos

Renal System – Clinical Medicine (PA)

010 Videos



Nephrology

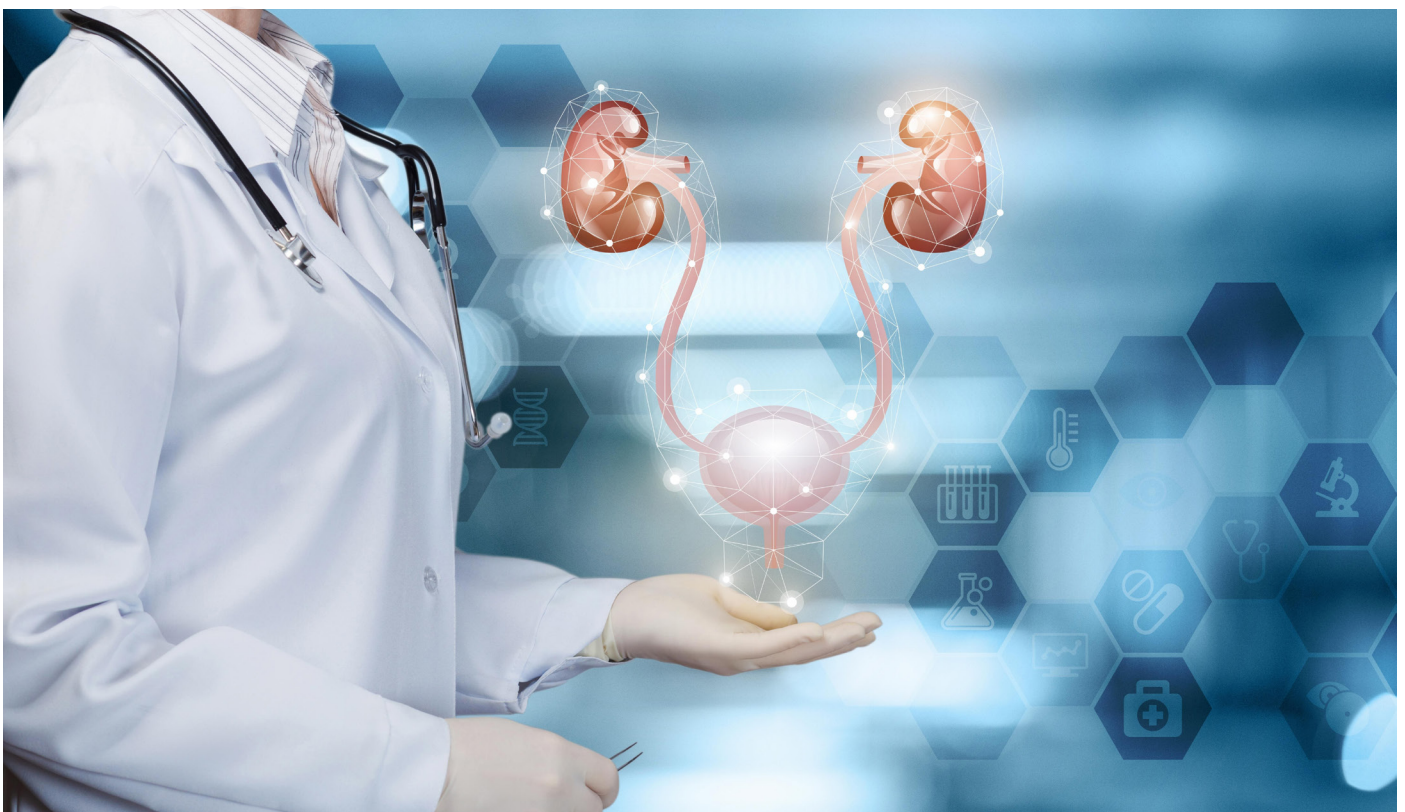- Acute Kidney Injury (AKI)
- Chronic Kidney Disease (CKD)
- Nephrolithiasis (Kidney Stones)
- Water Balance: Hypo- and Hypernatremia
- Potassium Disorders: Hypo- and Hyperkalemia
- Secondary Hypertension
- Nephrotic Syndrome
- Nephritic Syndrome
- Renal Replacement Therapy
- Urinary Tract Infection (UTI)

Pediatric Nephrology & Urology

- Pediatric Hematuria (Blood in Urine)
- Pediatric Glomerulonephritis
- Pediatric Proteinuria (Protein in Urine)
- Tubular Proteinuria and Focal Segmental Glomerulosclerosis (FSGS)
- Workup of Proteinuria and Nephrotic Syndrome in Children
- Hemolytic-Uremic Syndrome (HUS) in Children
- Vesicoureteral Reflux (VUR) and Types of Reflux
- Posterior Urethral Valves (PUV) and Ureteropelvic Junction (UPJ) Obstruction
- Vesicoureteral Reflux (VUR): Management
- Pediatric Polycystic Kidney Disease
- Renal Tubular Acidosis (RTA) in Children: Type 1
- Renal Tubular Acidosis (RTA) in Children: Type 2 and 3
- Renal Tubular Acidosis (RTA) in Children: Type 4 and Review
- Pediatric Rhabdomyolysis
- Undescended Testicle in Children and Painful Testicle Syndrome

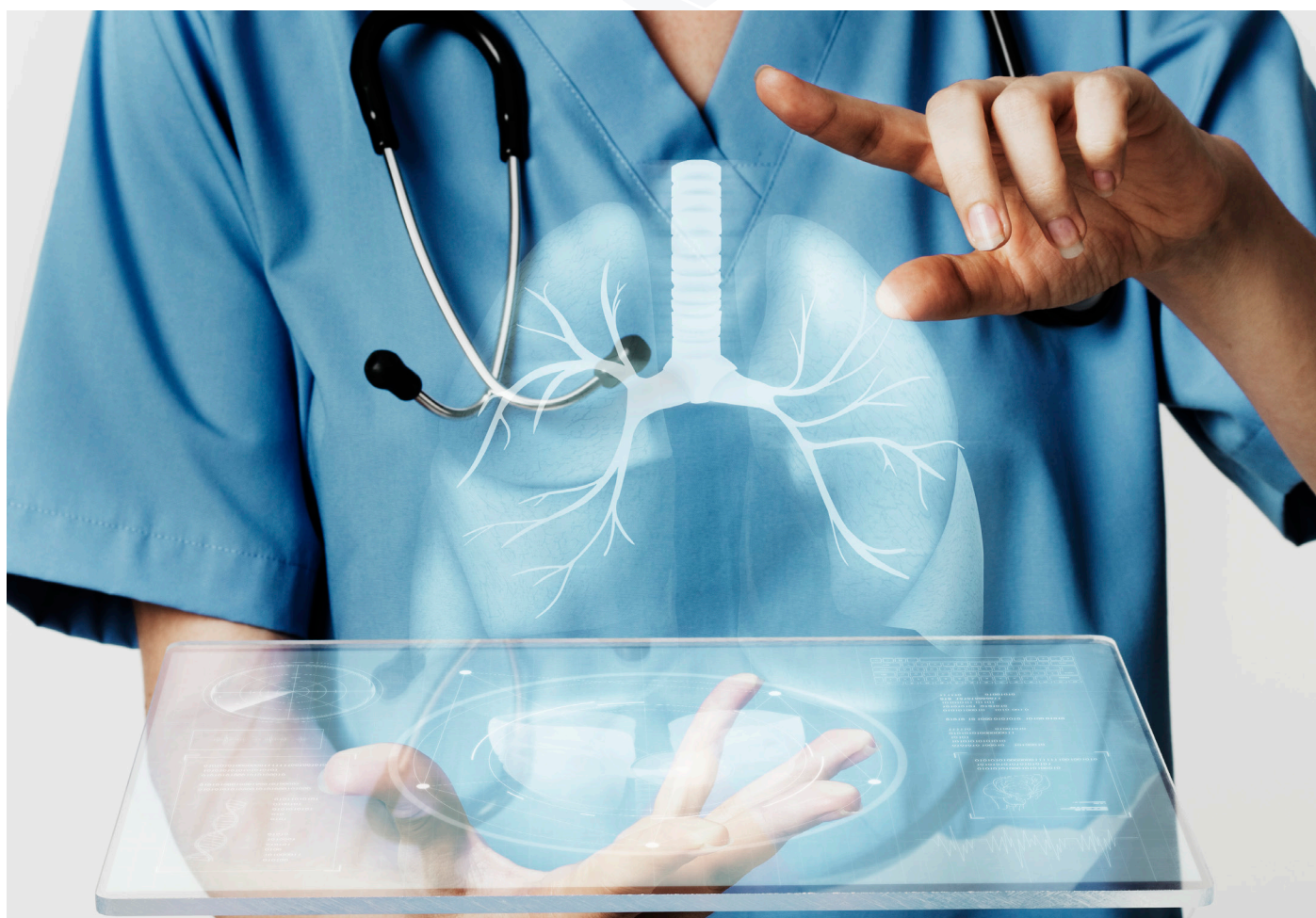Renal System – Clinical Medicine (PA)

- Acute Kidney Injury (AKI)
- Chronic Kidney Disease (CKD)
- Nephrolithiasis (Kidney Stones)
- Water Balance: Hypo- and Hypernatremia
- Potassium Disorders: Hypo- and Hyperkalemia
- Secondary Hypertension
- Nephrotic Syndrome
- Nephritic Syndrome
- Renal Replacement Therapy
- Urinary Tract Infection (UTI)



Pulmonology

Infections of the Respiratory Tract	20 Videos
Coronavirus	15 Videos
Airway Diseases	22 Videos
Interstitial Lung Disease (ILD)	11 Videos
Lung Cancer	15 Videos
Pulmonary Vascular Disease	09 Videos
Pleural Disease	10 Videos
Other Respiratory Disorders	07 Videos
Pediatric Pulmonology	19 Videos



Infections of the Respiratory Tract

- Respiratory Tract Infections: Introduction
- Respiratory Tract Infections: Classification
- Bronchitis
- Pneumonia: Overview
- Pneumonia: Classification
- Pneumonia: Signs and Symptoms
- Pneumonia: Diagnosis
- Pneumonia: Treatment
- Complications of Community Acquired Pneumonia
- Other Types of Pneumonia
- Bronchitis and Pneumonia: Summary
- Influenza Virus
- Subacute Lung Infections
- Tuberculosis: Epidemiology, Cause and Pathogenesis
- Tuberculosis Pathogenesis
- Clinical Manifestations and TB Case Histories
- Diagnosis of Tuberculosis
- Treatment of Tuberculosis
- Outcome of TB
- Tuberculosis: Summary

Coronavirus

- Coronaviridae: Overview
- Characteristics of COVID-19
- COVID-19: Transmission
- COVID-19: Basic Reproduction Number

- COVID-19: Case Fatality Rate (CFR) & Infection Fatality Rate (IFR)
- COVID-19: Epidemiology
- COVID-19: Pathogenesis
- COVID-19: Clinical Aspects
- COVID-19: Complications
- COVID-19: Diagnosis and Treatment
- COVID-19: Prevention
- COVID-19: Vaccines
- COVID-19: Efficacy, Effectiveness, and Side Effects of Vaccines
- COVID-19: Challenges and Prospects of Vaccine Development
- COVID-19: Clinical Case

Airway Diseases

- Asthma: Lower Airways Obstruction
- Asthma: Clinical History
- Asthma: Subtypes and Diagnosis
- Asthma: Treatment
- Asthma: Acute Exacerbations
- Asthma: Complications
- Chronic Obstructive Pulmonary Disease (COPD): Overview
- Chronic Obstructive Pulmonary Disease (COPD): Symptoms
- Chronic Obstructive Pulmonary Disease (COPD): Clinical Signs
- Chronic Obstructive Pulmonary Disease (COPD): Tests & Investigations
- Chronic Obstructive Pulmonary Disease (COPD): Treatment
- Chronic Obstructive Pulmonary Disease (COPD): Acute Exacerbation
- Chronic Obstructive Pulmonary Disease (COPD): Complications and Associations
- Chronic Obstructive Pulmonary Disease (COPD): Summary
- Large Airways Obstruction: Causes

- Large Airways Obstruction: Investigation and Treatment
- Bronchiectasis: Overview and Causes
- Bronchiectasis: Presentation and Clinical Signs
- Bronchiectasis: Diagnosis and Treatment
- Cystic Fibrosis and ABPA
- Hemoptysis and Major Hemoptysis: Definition and Treatment
- Other Airways Diseases: Summary

Interstitial Lung Disease (ILD)

- Interstitial Lung Disease (ILD): Overview
- Interstitial Lung Disease (ILD): Pathology
- Pulmonary Fibrosis
- Pulmonary Fibrosis: Signs and Investigation
- Pulmonary Fibrosis: Clinical Recognition and CT Scans
- Pulmonary Fibrosis: Invasive Tests and Treatment
- Hypersensitivity Pneumonitis
- Pneumoconiosis
- Sarcoidosis
- Sarcoidosis: Extrapulmonary Manifestations
- Sarcoidosis: Histological Confirmation

Lung Cancer

- Lung Cancer and Tumors: Overview
- Lung Cancer and Tumors: Pathogenesis
- Lung Cancer and Tumors: Presentation
- Local Invasion and Metastases
- Distal Metastases
- Paraneoplastic Syndromes

- Differential Diagnosis of Suspected Lung Cancer
- Investigation of Suspected Lung Cancer
 - Lung Cancer and Tumors
- Lung Cancer Staging (TNM)
- Treatment: Curable and Incurable NSCLC
- Treatment: SCLC
- Mesothelioma: Presentation and Management
- Pulmonary Fibrosis
- Less Common Lung Tumors
- Lung Cancer and Tumors: Summary

Pulmonary Vascular Disease

- Pulmonary Vascular Disease: Introduction
- Pulmonary Emboli
- Diagnosis of Acute PE
- Treatment of PE
- Pulmonary Hypertension
- Chronic PE (Primary Pulmonary Hypertension)
- Treatment of Pulmonary Hypertension
- Cor Pulmonale
- Pulmonary Vasculitis

Pleural Disease

- Pleural Disease: Introduction
- Transudates vs. Exudates
- Unilateral Pleural Effusions
- Pleural Tap
- Pleural Biopsy

- Pneumothorax
- Tension Pneumothorax
- Empyema
- Pleural Thickening
- Asbestos Exposure and Pleural Disease

Other Respiratory Disorders

- Disorders of Respiratory Physiology
- Acute Respiratory Distress Syndrome
- Patterns of Acid-base Disorders
- Treatment of Type 2 Respiratory Failure
- Obstructive Sleep Apnea
- Obesity Hypoventilation Syndrome
- Chest Wall and Muscle Disease

Pediatric Pulmonology

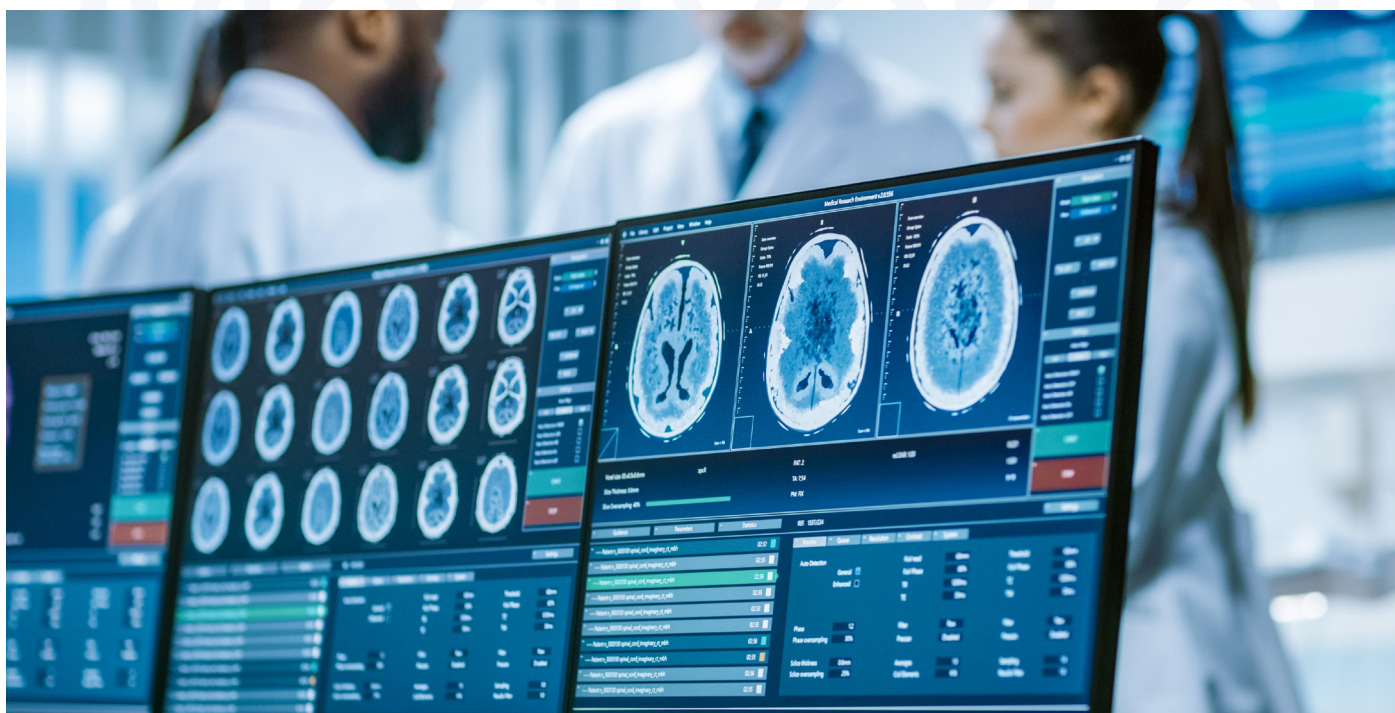- Pediatric (Childhood) Asthma: Pathology, Signs & Symptoms
- Pediatric (Childhood) Asthma: Clinical Presentation
- Pediatric (Childhood) Asthma: Diagnosis & Treatment
- Pediatric Asthma: Management
- Bronchiolitis: Causes and Risks
- Bronchiolitis: Diagnosis
- Bronchiolitis: Clinical Presentation & Management
- Cystic Fibrosis (CF): Pathology
- Cystic Fibrosis (CF): Clinical Presentation, Signs & Symptoms
- Cystic Fibrosis (CF): Diagnosis & Management
- Chronic Lung Disease of Prematurity (Bronchopulmonary Dysplasia BPD)
- Surfactant Deficiency

- Pulmonary Hypoplasia
- Diaphragmatic Hernia and Congenital Cystic Adenomatoid Malformation (CCAM)
- Pediatric Pulmonary Embolism (PE)
- Allergic Bronchopulmonary Aspergillosis (ABPA)
- Ciliary Dyskinesia
- Alpha-1 Antitrypsin Deficiency
- Pediatric Pneumothorax



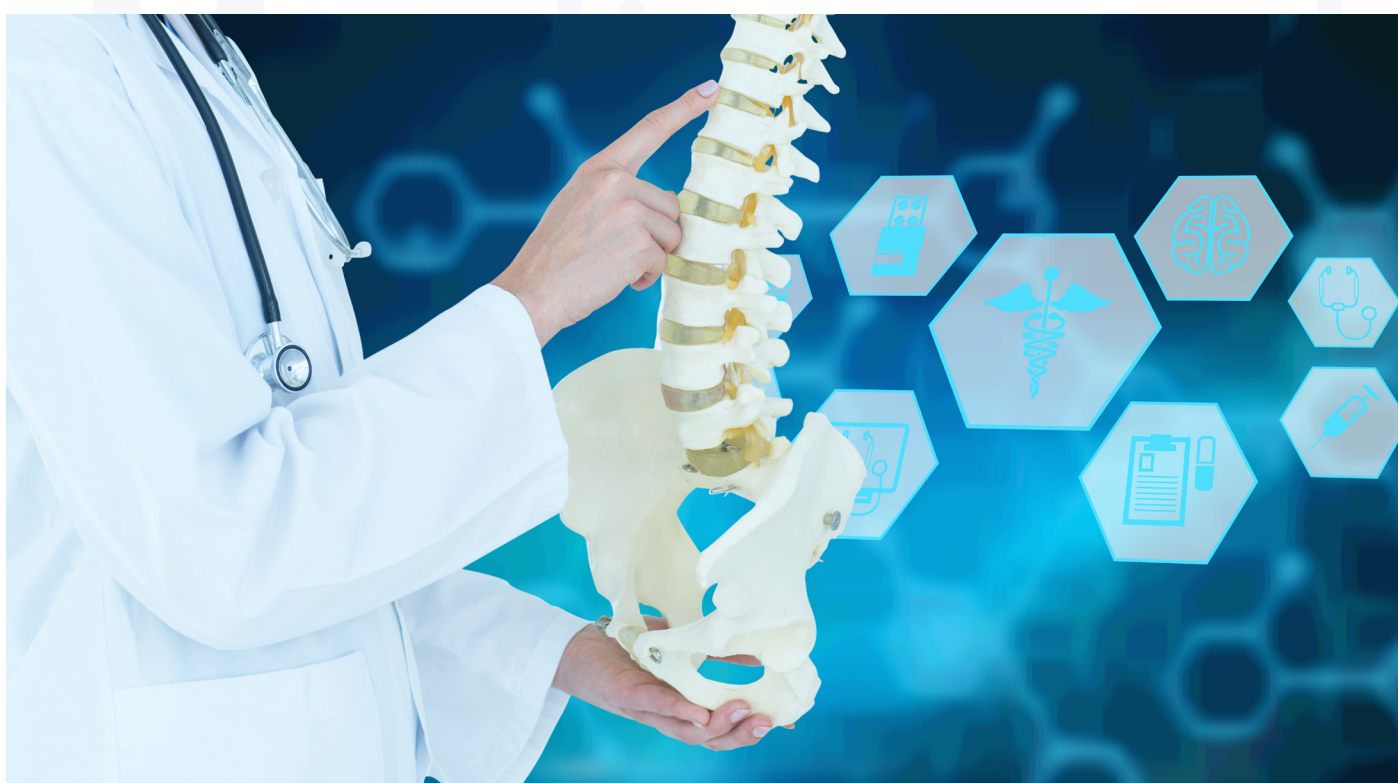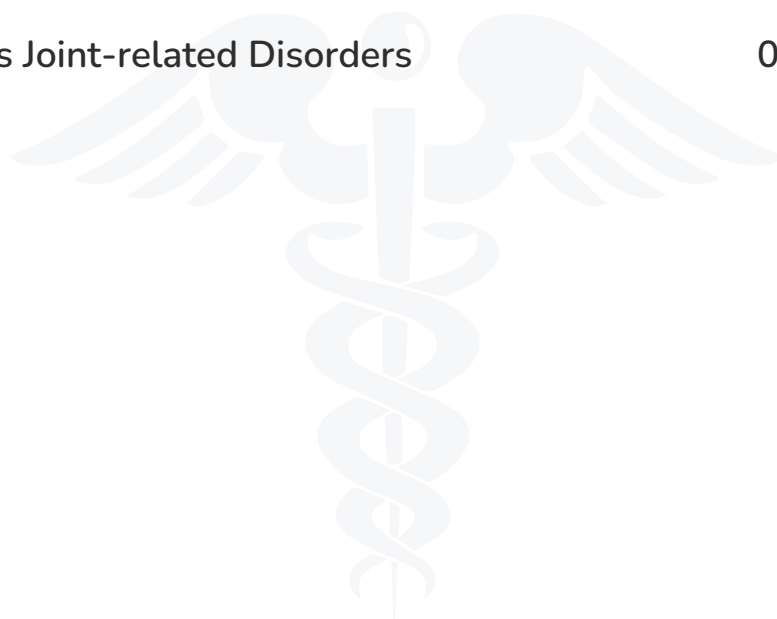
Radiology

Introduction to Imaging	07 Videos
Thoracic Radiology	31 Videos
Abdominal Radiology	33 Videos
Musculoskeletal Radiology	06 Videos
Neuroradiology	06 Videos
Pediatric Radiology	03 Videos



Rheumatology

General Approach to Arthritis and Joint Pain	10 Videos
Connective Tissue Diseases	17 Videos
Spondyloarthritides	08 Videos
Non-Autoimmune Arthritis	13 Videos
Vasculitides	12 Videos
Miscellaneous Joint-related Disorders	07 Videos



General Approach to Arthritis and Joint Pain

- Rheuma Case: 68-year-old Woman with Knee Pain
- Rheuma Case: 73-year-old Woman with Shoulder Pain
- Rheuma Case: 33-year-old Man with Posterior Heel Pain
- Approach to Arthritis: Review
- Rheuma Case: 54-year-old Man with Shoulder Pain
- Review: Shoulder Pathology and Anatomy
- Rotator Cuff Anatomy and Disease
- Adhesive Capsulitis (Frozen Shoulder)
- Rheuma Case: 54-year-old Woman with Acute Right Shoulder Pain
- Rheuma Case: 63-year-old Woman with Increasing Right Shoulder Pain

Connective Tissue Diseases

- Rheuma Case: 59-year-old Man with Bilateral Wrist Pain and Swelling
- Rheumatoid Arthritis: Diagnosis, Pathogenesis, and Treatment
- Quick Review: Rheumatoid Arthritis
- Rheuma Case: 24-year-old Woman with Pleuritic Chest Pain and Dyspnea
- Systemic Lupus Erythematosus (SLE) Diagnostic Criteria (4-Skin-RASH-NIA)
- Differential Diagnosis for Systemic Lupus Erythematosus (SLE)
- Systemic Lupus Erythematosus (SLE): Complications and Management
- Quick Review: Drug-induced Lupus and Systemic Lupus Erythematosus (SLE)
- Rheuma Case: 57-year-old Man with Muscle Weakness
- Inflammatory Myopathies: Types, Diagnosis, Manifestations, Treatment
- Quick Review: Inflammatory Myopathies

- Rheuma Case: 37-year-old Woman with Reflux and Facial Rash
- Systemic Sclerosis (CREST Syndrome): Complications and Management
- Quick Review: Systemic Sclerosis
- Rheuma Case: 54-year-old Woman with Seasonal Allergies
- Sjögren's Syndrome: Key Features and Management
- Quick Review: Sjögren's Syndrome

Spondyloarthritides

- Spondyloarthritides
- Rheuma Case: 26-year-old Woman with Persistent Low Back Pain
- Ankylosing Spondylitis: Complications and Treatment
- Rheuma Case: 37-year-old Woman with Joint Pain
- Reactive Arthritis: Diagnosis and Management
- Rheuma Case: 46-year-old Man with Increasing Pain/Swelling in Fingers
- Psoriatic Arthritis: Diagnosis and Management
- Quick Review: Spondyloarthritides

Non-Autoimmune Arthritis

- Rheuma Case: 27-year-old Man with Cough and Dyspnea
- Rheuma Case: 62-year-old Woman with Sore Legs and Dyspnea
- Sarcoidosis: Complications and Management
- Quick Review: Sarcoidosis
- Rheuma Case: 31-year-old Woman with Body Aches
- Fibromyalgia: Diagnosis and Management
- Quick Review: Fibromyalgia
- Rheuma Case: 48-year-old Man with Fevers, R Knee Pain and Swelling
- Non-gonococcal Septic Arthritis: Initial Treatment and Management
- Quick Review: Septic Arthritis

Vasculitides

- Rheuma Case: 37-year-old Woman with Dyspnea and Abdominal Pain
- Vasculitis: Overview
- Polyarteritis Nodosa
- Anti-GBM Disease (Goodpasture's)
- ANCA-associated Vasculitis
- Eosinophilic Granulomatosis with Polyangiitis: Diagnosis and Management
- Rheuma Case: 14-year-old Girl with Abdominal Pain and Rash
- Kawasaki Disease: Features and Manifestations
- Large Vessel Vasculitides: Takayasu's and Giant Cell Arteritis
- Cryoglobulinemic Vasculitis
- IgA Vasculitis (Henoch-Schönlein)
- Quick Review: Vasculitis

Miscellaneous Joint-related Disorders

- Rheuma Case: 52-year-old Man with Chronic Right Knee Pain
- Osteoarthritis: Risk Factors and Radiography
- Rheuma Case: 49-year-old Woman with R Proximal Thumb Pain
- Osteoarthritis: Treatment
- Quick Review: Osteoarthritis
- Rheuma Case: 51-year-old Man with R Knee and L Ankle Pain
- Gout: History, Pathophysiology
- Gout: Diagnosis and Treatment
- Pseudogout (CPPD)
- Quick Review: Gout and Pseudogout

Vascular Medicine

Arterial Diseases

- Atherosclerosis: Definition
- Atherosclerosis: Etiology
- Atherosclerosis: Pathogenesis
- Atherosclerosis: Histopathologic Consequences
- Atherosclerosis: Diagnosis
- Atherosclerosis: Therapy
- Atherosclerosis: Summary
- Buerger's Disease: Definition and Etiology
- Buerger's Disease: Symptoms and Therapy
- Raynaud's Disease: Case, Definition & Pathogenesis
- Raynaud's Disease: Symptoms, Diagnosis and Therapy
- Buerger's and Raynaud's Disease: Summary
- Peripheral Artery Disease: Definition
- Peripheral Artery Disease: Pathogenesis
- Peripheral Artery Disease: Summary
- Aortic Aneurysm: Example
- Aortic Aneurysm: Definition
- Aortic Aneurysm: Etiology
- Aortic Aneurysm: Diagnosis
- Aortic Aneurysms: Summary
- Dissection of the Aorta: Etiology
- Dissection of the Aorta: Symptoms
- Dissection of the Aorta: Therapy
- Renal Stenosis and Fibromuscular Dysplasia
- Dissection and Renal Artery Stenosis: Summary
- Hypertension: Example

- Hypertension: Definition & Forms
- Hypertension: Pathogenesis and Symptoms
- Hypertension: Etiology (Neural Blood Pressure Control Mechanisms)
- Hypertension: Etiology (Humoral Blood Pressure Control Mechanisms)
- Hypertension: Etiology (Risk Factors)
- Hypertension: Symptoms
- Hypertension: Epidemiology
- Hypertension: Summary
- Hypotension and Shock: Definition
- Hypotension and Shock: Pathogenesis
- Hypotension and Shock: Therapy
- Hypotension and Shock: Summary

Venous Diseases

- Venous Diseases: Overview
- Thrombosis: Examples
- Thrombosis: Consequences of Venous Thromboembolism
- Thrombosis: Summary
- Varicose Veins: Definition
- Varicose Veins: Etiology
- Varicose Veins: Pathogenesis
- Varicose Veins: Symptoms
- Varicose Veins: Diagnosis
- Varicose Veins: Summary
- Deep Vein Thrombosis: Definition
- Deep Vein Thrombosis: Epidemiology
- Deep Vein Thrombosis: Etiology
- Deep Vein Thrombosis: Risk Factors
- Deep Vein Thrombosis: Pathogenesis

- Deep Vein Thrombosis: Symptoms
- Deep Vein Thrombosis: Therapy
- Deep Vein Thrombosis: Summary
- Pulmonary Embolism: Definition
- Pulmonary Embolism: Diagnosis
- Pulmonary Embolism: Pulmonary Contrast Angiogram
- Pulmonary Embolism: Summary

Inflammatory Vascular Diseases

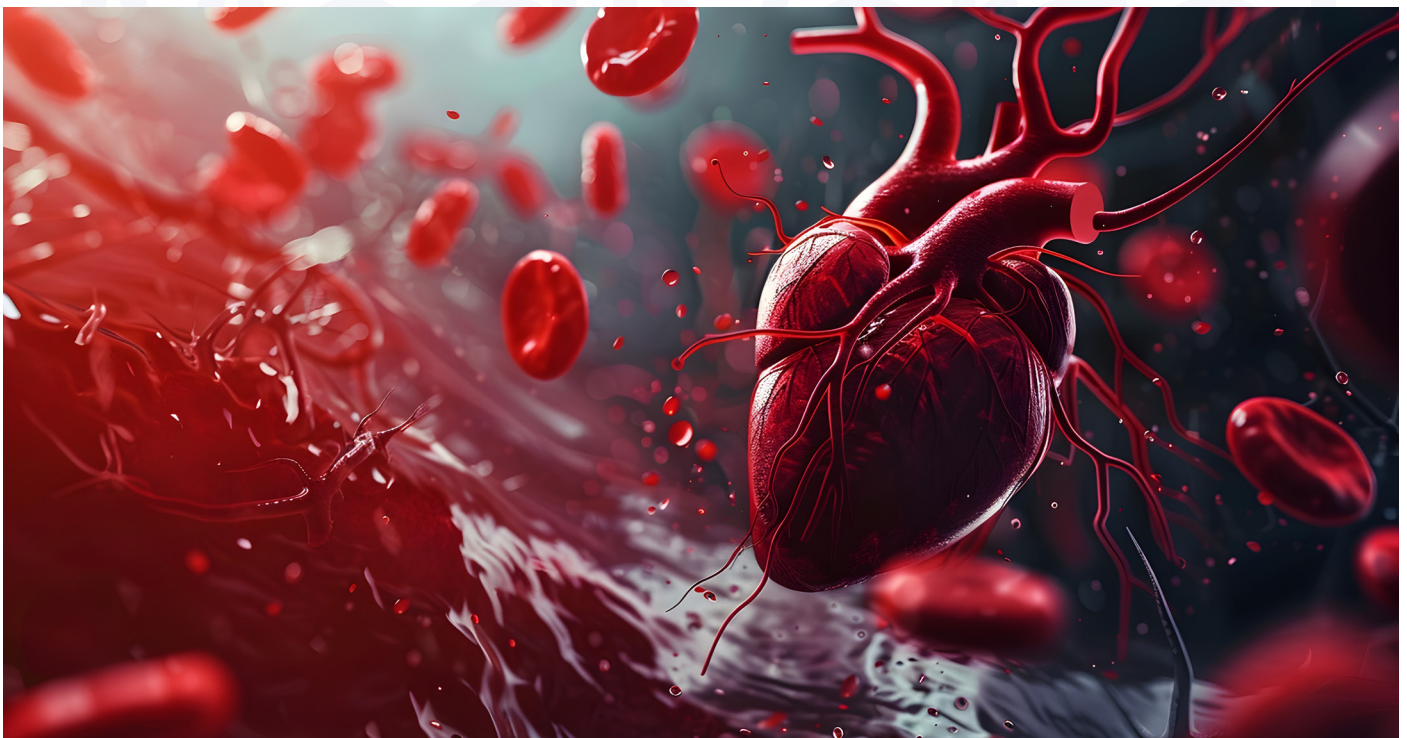- Inflammatory Vascular Diseases: Definition
- Inflammatory Vascular Diseases: Classification
- Inflammatory Vascular Diseases: Summary
- Polyarteritis Nodosa
- Kawasaki Disease
- Giant Cell Arteritis

Vascular Malformations

- Vascular Malformations: Definition
- Non-neoplastic Vascular Malformations – Vascular Malformations
- Cavernomas – Vascular Malformations
- Congenital Vascular Malfunctions of the Aorta – Vascular Malformations
- Vascular Malformations: Summary

Diseases of the Lymphatic System

- Diseases of the Lymphatic System: Definition
- Starling's Law of the Capillary
- Components of the Lymphatic System
- Structure of Lymphatic Vessels
- Congenital Lymphatic Malformations
- Conditions with Tissue Edema
- Diseases of the Lymphatic System: Summary



Why Mediversal?

	Mediversal	
CPD hours/ Credit	✓ 110 hours/Credit	⚠ 3—50 hours/Credit
NMC Guideline	✓ Advantages in accordance with provision 1.4.2 of NMC regulations	⚠ Not all. (Very few)
Renowned International faculties	✓ Yes	⚠ Only for few subjects
Faculty to learner ratio	✓ 1:10	✓ 1:50 or 1:75
Case based learning	✓ Yes	✗ No
AI supported learning	✓ Yes	✗ No
Live Interaction Sessions	✓ Yes	✗ No
Clinical Attachments	✓ Yes (Case to Case basis)	✓ Yes
Associated with Hospitals for Clinical Training	✓ Yes	✓ Yes
Books	✓ Yes (Printable Pdf copy)	✗ No
Complementary e-Learning Module & Certification	✓ Yes	✗ No
Learner Support	✓ Yes	✗ No
Community of Doctors for peer support (Mediversal Alumni only)	✓ Yes	✗ No
Alumni Support	✓ Yes	⚠ Only a few
e-Certification	✓ Yes	✓ Yes
Physical Certification	✓ Yes	⚠ Only a few
Lifetime certificate validity	✓ Yes	✓ Yes
Digital Marketing and Business Support for your hospital/clinic	✓ Yes	✗ No
Admission process	✓ Smooth, Transparent & all details provided	⚠ Spamming through multiple channels.
Data and privacy protection	✓ Yes	✗ No
CME access	✓ Yes (Lifetime)	✗ No
Medico Legal Session	✓ Yes (Free. By renowned high court advocates)	✗ No
National Level Felicitation Award (for Mediversal Alumni)	✓ Yes	✗ No



Mediversal Academy

A-504B, Unitech Arcadia, South City-2,
Sector-49, Gurgaon (Delhi-NCR)

Branch: Vijayanagar, Bangalore (Karnataka)

+91 97178 59318

contact@mediversal.co.in

www.mediversal.co.in

